



Association Between Vitamin D Deficiency and CCl₄ Mediated Hepatic Inflammation in Male Albino Rats; Evaluation of Some Biochemical and Antioxidant Marker

NEDAA ALI ELDESOUKY¹, GEHAD E. ELSHOPAKEY¹, MOHAMED S. YUSUF², FATMA M. ABDELHAMID¹, ENGY. F. RISHA^{1*}

¹Department of Clinical Pathology, Faculty of Veterinary Medicine, Mansoura University, Mansoura, 35516, Egypt;

²Nutrition and Clinical nutrition Department, Faculty of Veterinary Medicine, Suez Canal University, 41522, Ismailia, Egypt.

Abstract | This study conducted to assess the effect of vitamin D deficiency on progression of CCl₄ mediated hepatic oxidative stress and inflammation in male albino rat. Forty male albino rats, weighing 120-170g, were randomly divided into four equal groups (n= 10/group): control group, vitamin D deficiency group, CCl₄ treated group (1ml CCl₄: 1 ml olive oil), at dose 0.2 ml /kg BW once daily and the vitamin D deficiency+CCl₄ one group. After six weeks of treatment, biochemical parameters, hepatic oxidative and, antioxidant biomarker, calcium, phosphorus, and Vit D were determined. Our result showed that CCl₄+Vit D deficiency and CCl₄ treated groups showed significant elevation in the serum ALT, AST and ALP with significant decrease in the total protein and globulin compared with the control group. A significant elevation in total, indirect bilirubin and direct bilirubin level was observed in the CCl₄+Vit D deficiency group compared to CCl₄ group. Vitamin D level was significantly declined in all experimental groups compared to control group. Moreover, calcium level was decrease in Vit D deficiency group and CCl₄+Vit D deficiency group compared to the control. The hepatic antioxidant biomarkers (GSH and SOD) were significantly reduced in CCl₄ and CCl₄+Vit D deficiency groups, while hepatic MDA level was significantly increased in the same groups unlike the control group. Overall, our findings revealed that the co-existence of vitamin D deficiency might aggravate hepatic inflammation and necrosis; this was confirmed by our biochemical, oxidative stress/antioxidant and histopathological results.

Keywords | Hepatic toxicity, CCl₄, Vitamin D deficiency, Oxidative stress, Rats

Received | March 12, 2021; **Accepted** | March 17, 2021; **Published** | June 01, 2021

***Correspondence** | Engy Risha, Department of Clinical Pathology, Faculty of Veterinary Medicine, Mansoura University, Mansoura, 35516, Egypt; **Email:** engyrisha@yahoo.com

Citation | Eldesouky NA, Elshopakey GE, Yusuf MS, Abdelhamid FM, Risha EF (2021). Association between vitamin d deficiency and ccl₄ mediated hepatic inflammation in male albino rats; evaluation of some biochemical and antioxidant marker. *Adv. Anim. Vet. Sci.* 9(7): 994-1003.

DOI | <http://dx.doi.org/10.17582/journal.aavs/2021/9.7.994.1003>

ISSN (Online) | 2307-8316; **ISSN (Print)** | 2309-3331

Copyright © 2021 Risha. This is an open access article distributed under the Creative Commons Attribution License, which permits unrestricted use, distribution, and reproduction in any medium, provided the original work is properly cited.

INTRODUCTION

CCl₄ metabolism is an established model of liver necrosis and fibrosis. The liver damage is created by this metabolism is free radical dependent as CCl₄ is oxidized by cytochrome P450 to highly reactive trichloromethyle (CCl₃) radical that being generated by reductive cleavage of CCl₄ bond and generated oxygen radicals and phospholipid peroxides in abundance (Jeong et al., 2020). The gen-

erated trichloromethyle free radical causes liver necrosis, destruction of ECM and lipid peroxidation of membranes as well as its cytotoxic effect. The free radical is induced hepatic injury by interacting with unsaturated fatty acids of cell membrane causing lipid peroxidation or cross linking of the unsaturated fatty acids or by covalent binding to important micromolecules including protein, lipid and nuclear as well as mitochondrial DNA. All of these processes cause damage of cell membrane and leakage of the

CCl₄ activates several transcription factor including NF- κ B which is consider transcription forlorn complex essentially involved in several inflammatory cytokines including IL-6 (Natsume et al., 1999). Upon activation of CCl₄, Kupffer cells (resident macrophages) release many chemical mediators such as TNFs, NO, TGF- β 1 and IL-6. Also 11SC which are normally quiescent became activated and display a typical acute phase response take a fibroblast like appearance release NO, increased production of typed collagen and thus promote hepatic fibrosis. The TGF β 3-1 play a role in the fibrogenic response of HSC to Cc15 and so all grits associated with TGF- β 1 singling pathway or inflammatory response pathway were expressed upon CCL₄ administration (Chung et al., 2005).

Vitamin D, sunshine hormone, was formed through exposure of skin to ultraviolet rays' 290_310 nm. Vitamin D is a fat-soluble vitamin that is present in foods. Vitamin D obtained from sun exposure, food, and supplements is biologically inert and must undergo two hydroxylations in the body for activation. First hydroxylation in the liver which converts vitamin D to 25-hydroxyvitamin D3 [25(OH) D3], known as calcidiol. The second is in the kidney and forms the physiologically active 1,25-dihydroxyvitamin D3 [1,25(OH)2D3], which known calcitriol (Nair and Maseeh, 2012).

Vitamin D plays a fundamental role in regulating calcium and phosphorus homeostasis and, in particular, the pathways involved in bone mineralization and bone mass acquisition. Besides these classic skeletal actions, recent studies have demonstrated that vitamin D exerts other significant extra skeletal actions, with a possible role in the pathogenesis of several pathological conditions, including infectious and autoimmune diseases (Saggese et al., 2015). Vitamin D has other roles in the body as modulation of cell growth, neuromuscular and immune function, and decrease inflammation (Holick, 2006). Many genes encoding proteins that regulate cell proliferation, differentiation, and apoptosis are modulated in part by vitamin D (Nair and Maseeh, 2012). Many cells have vitamin D receptors, and some convert 25(OH) D3 to 1, 25(OH) 2D3. Vitamin D is unique because it can be made in the skin from exposure to sunlight (Autier, 2007). This study aimed to evaluate the effect of vitamin D deficiency and CCl₄ on biochemical parameters, besides hepatic oxidative and antioxidant hurt in male albino rat. Moreover, the association between of vitamin D deficiency existence and the severity of liver inflammation were evaluated.

EXPERIMENTAL DIETS

Composition of the control diet and vitamin D free diet were presented in the following Table 1:

DRUGS

CCl₄ was purchased from El-Gomhoria Co., Mansoura, Egypt. Olive oil imported metro company, Arish city, Egypt.

ANIMAL AND EXPERIMENTAL DESIGN

This study was conducted on forty adult albino rats 120-170g. The adults obtained from lab animal unit at Faculty of Veterinary Medicine, Zagazig University. The animal were adapted for lab condition control basal diet and water 2 weeks after adaptation rats were weighted and divided into four equal groups (n= 10/group) as follow:

1. Control group (group I): Rats fed on control diet with orally administration of distilled water.
2. Vitamin D deficiency group (group II): Rats fed on Vit D deficient diet and deprived from sun light for six weeks with orally administration of distilled water.
3. CCl₄ group (group III): Rats were treated orally with CCl₄ suspended in olive oil (1ml CCl₄:1ml olive oil) at dose 1 ml/kg BW/ day for 4 weeks (Abdalla et al., 2013, Osama et al., 2014) and fed on control diet for six weeks.
4. CCl₄ +Vitamin D deficiency group (group IV): Rats were treated orally with CCl₄ and fed on Vit D deficient diet for six week with deprivation from sun light, with the same previous dose and manner.

BLOOD AND TISSUE SAMPLES COLLECTION

Blood samples were collected from each group at the end of the six week. From each rat two blood samples were collected from the medial canthus of the eye. The first blood sample were collected and mixed with anticoagulant (EDTA) for blood counting, while the second sample was collected without anticoagulant and placed in a slant position for twenty minutes at room temperature, then samples were stored in refrigerator for retraction of clot and centrifuged for ten minutes at three thousands r.p.m to separate clear serum samples that carefully transferred to eppendorf tubes to be stored at -20°C until used for biochemical estimation. Also, 0.5 gram of hepatic tissue from each rat was isolated and washed with normal saline then homogenized for determination of liver oxidative stress and antioxidant biomarkers, also specimens from Liver was collected and fixed in 10% formalin for histopathological examination.

HEMATOLOGICAL ANALYSIS

Erythrocyte count, hemoglobin (Hb), packed cell volume (PCV), blood indices, leukocytes count were accomplished by manual hemocytometer method using improved

Table 1: Composition of the control diet and vitamin D free diet

Diet	A	B	Proximate composition	
			-ve Vit D diet	+ve Vit D diet (control diet)
Ingredient	g/kg	g/kg		
Ground Yellow Corn (8.6% CP) ^a	200	200	CP% = 17.8	CP% =17.9
Lactose	150	0.0	ME= 3690 KCal/kg	ME= 3694 KCal/kg
Sucrose	50	50		
Rice	0.0	165	Ca = 0.6%	Ca =0. 63%
Yellow peas (25.4% CP)	180	165	P = 0.35%	P = 0.37%
Poultry meal (57.7% CP)	150	135	Methionine = 0.3%	Methionine = 0.2%
Ground alfalfa hay (16.8%CP)	90	100		
Fine wheat bran (15.9% CP)	90	95		
Monocalcium phosphate	10	14	Lysine = 0.2%	Lysine = 0.1%
^b Vitamin D3 free, Vit.& mineral Premix	28	0.0		
^c Vit.& mineral Premix	0.0	24		
Salt	7	7		
Lysine	5	5		
Linseed oil	40	40		

^a Determined values according to AOAC (2000).

^b Each 3 kg of vitamin D free vitamins and minerals premix: vit. A 12 mIU, vit. E1000 mg, vit. k3 1g, vit. B1 1g, vit. B2 5g, vit. B6 1.5g, vit. B12 10 mg, biotin 50 mg, pantothenic acid 10g, nicotinic acid30g, folic acid 1g, manganese 60g, zinc 50g, iron 30g, copper 4g, iodine 300 mg, Se 100 mg, cobalt 100mg, and carrier (CaCO₃) to 3 kg (MinaKarma care, Egypt).

^c Each 3 kg contains the following vitamins and minerals: vit. A 12 mIU, vit. D3 2 mIU, vit. E1000 mg, vit. k3 1000 mg, vit. B1 1000 mg, vit. B2 5000 mg, vit. B6 1500 mg, vit. B12 10 mg, biotin 50 mg, pantothenic acid 10000 mg, nicotinic acid30000 mg, folic acid 1000 mg, manganese 60000 mg, zinc 50000 mg, iron 30000 mg, copper 4000 mg, iodine 300 mg, selenium 100 mg, cobalt 100mg, and carrier (CaCO₃) to 3 kg (Golden premix- Selim Pharm Elasher, Egypt).

Neubauer counting chamber. Film were also prepared from each blood sample, fixed and then stained with Gemisa stain for differential leukocytic count (Feldman et al., 2000).

SERUM BIOCHEMICAL ANALYSIS

Alanine aminotransferase (ALT) and aspartate aminotransferase (AST) were measured with colorimetric kits (Randox, UK). But, alkaline phosphatase (ALP) was estimated with commercial diagnostic kits (Teco diagnostics, USA). The bilirubin was measured by Diamond kits, Meanwhile total protein and albumin were detected by Stanbio Laboratory (USA) kits. While, Glucose, cholesterol, and triglycerides were measured using ready-made kits provided by Spinreact. All parameters were spectrophotometrically detected (5010 photometer, BM Co., Berlin, Germany) according to the enclosed pamphlets. Globulin was calculated by subtraction of serum albumin from total protein and the albumin/globulin (A/G) ratio was calculated by dividing albumin by globulin concentrations (Mahmoud et al., 2020).

Vitamin D 25 hydroxy assay: Total vitamin D is measured by immunoassays (ELISA) by reagents from Calbiotech or IDS or by LC MS MS (PAML, Spokane, WA). Albumin is determined in COBAS Mira plus instrument using bromocresol green. Vitamin D binding protein (DBP) as-

say: Immunometric assay (sandwich ELISA) using DBP antibody coated microtiter plates and biotin labeled anti-DBP (Bhan et al., 2012). Calcium were determined by quantitative colorimetric method by Spinreact method, described by Young (2001). Phosphorus were determined by according to Tietz (1990) quantitative determination of inorganic phosphorous.

MEASUREMENT OF HEPATIC OXIDATIVE STRESS AND ANTIOXIDANT MARKERS

The malondialdehyde (MDA), superoxide dismutase (SOD), catalase (CAT), and reduced glutathione (GSH) were determined spectrophotometrically by the enzymatic colorimetric method using Bio-diagnostic kits (Egypt), referring to the manufacturer's protocols.

HISTOPATHOLOGICAL STUDIES

Tissue specimen from liver was excised, washed with normal saline and fixed in buffered formalin then, pieces of tissues were sliced at 5micron thickness. The slides for microscopic examination were stained with hematoxylin and eosin as described by (Bancroft et al., 1990).

STATISTICAL ANALYSIS

Results were expressed as the mean ± standard error for five rats in each group. All data analyzed by statistical software

Parameters	Treatment groups			
	Control	Vit D deficiency	CCl ₄	CCl ₄ +Vit D deficiency
RBCs (×10 ⁶ /μl)	7.94±0.069 ^a	7.54±0.72 ^a	6.23±0.15 ^b	5.00±0.06 ^c
Hb (g/dl)	14.90±0.57 ^a	14.70±0.10 ^a	8.40±0.10 ^b	8.46±0.08 ^b
PCV (%)	42.00±1.00 ^a	40.33±1.33 ^{ab}	38.00±0.58 ^b	38.60±0.52 ^b
MCV(fl)	52.86±0.82 ^c	53.69±3.58 ^c	61.04±2.01 ^b	77.2±1.09 ^a
MCH (pg)	18.76±0.079 ^a	19.53 ±0.81 ^a	16.80±0.10 ^b	13.60 ±0.45 ^c
MCHC (%)	35.51 ±0.74 ^a	36.51±1.07 ^a	21.77 ±0.41 ^b	22.28 ±0.34 ^b
TLC (×10 ³ /μl)	13.96±0.63 ^b	12.73±0.94 ^b	17.15±0.38 ^a	18.38±.029 ^a
Lymphocyte (×10 ³ /μl)	9.75±0.49 ^a	9.18 ±0.49 ^a	5.98±0.36 ^b	3.63±0.61 ^c
Neutrophil (×10 ³ /μl)	3.02±0.74 ^c	2.97±0.59 ^c	10.16±0.32 ^b	13.88±0.52 ^a
Eosinophil (×10 ³ /μl)	0.25±0.04 ^a	0.24±0.07 ^a	0.13±0.07 ^a	0.35±0.15 ^a
Monocyte (×10 ³ /μl)	0.93±0.36 ^a	0.34±0.11 ^a	0.87 ±0.14 ^a	0.51±0.09 ^a

RBCs (Red blood cells), Hb (Hemoglobin), PCV (Packed cell volume), MCV (Mean corpuscular volume), MCH (Mean corpuscular hemoglobin), TLC (Total leukocytic count).

Values with different superscript letters consider significance at (p < 0.05).

Table 2: Serum biochemical marker of male albino rat 6th week after induction of Vit D deficiency and liver necrosis (Mean± SE)

Parameters	Treatment groups			
	Control	Vit D deficiency	CCl ₄	CCl ₄ +Vit D deficiency
ALT (U/l)	36.22±1.36 ^b	38.50±0.2 ^b	54.32±2.87 ^a	51.25±0.48 ^a
AST (U/l)	50.47±2.17 ^b	51.40±0.62 ^b	74.00±1.47 ^a	72.50±1.84 ^a
ALP (U/l)	367.2±23.06 ^b	351.05±34.64 ^b	438.82±2.40 ^a	452.23±2.24 ^a
Total protein(g/dl)	6.53±.03 ^a	6.31±0.21 ^a	5.30±.07 ^b	5.47±0.03 ^b
Albumin (g/dl)	3.58±0.07 ^a	3.45 ±0.08 ^a	3.58±0.11 ^a	3.51 ±0.09 ^a
Globulin(g/dl)	2.94 ±0.08 ^a	2.80±0.28 ^a	1.73 ±0.17 ^b	1.96 ±0.04 ^b
A/G ratio	1.22±0.06 ^b	1.26±0.18 ^b	2.16±0.31 ^a	1.79±0.05 ^{ab}
T.bil.(mg/dl)	0.27±0.01 ^c	0.29 ±0.01 ^c	0.36±0.18 ^b	0.48±0.01 ^a
Dir.bil.(mg/dl)	0.13±0.01 ^c	0.14±0.01 ^c	0.17±0.01 ^b	0.20±0.01 ^a
Indir.bil (mg/dl)	0.14±0.01 ^c	0.15±0.01 ^c	0.19±0.01 ^b	0.27±0.01 ^a
Cholesterol (mg/dl)	74.67±0.88 ^a	67.00±0.58 ^a	67.00 ±6.43 ^a	70.50±0.29 ^a
Triglycerides (mg/dl)	135.8±1.6 ^d	141.67±0.88 ^c	149.70±0.40 ^b	155.53±1.77 ^a
Glucose (mg/dl)	52.43±0.73 ^d	74.32±1.99 ^c	79.13±0.09 ^b	87.25±1.09 ^a

Values with different superscript letters consider significance at (p < 0.05).

ALT (Alanine aminotransferase), AST (Aspartate aminotransferase), ALP (Alkaline phosphatase), A/G ratio (albumin/globulin ratio), T.bil (total bilirubin), Dir.bil (direct bilirubin), Indir.bil (indirect bilirubin)

program (SPSS for Windows, version 20, USA). ANOVA was used to detect differences between means of all groups using Duncan multiple comparison tests to know significant difference (p<0.05) (Norušis, 2006).

RESULTS

HEMATOLOGICAL ANALYSIS

Red blood cell (RBCs), Hb, PCV, and mean corpuscular volume (MCV) were significantly increased in the CCl₄ and CCl₄+Vit D deficiency groups comparing with the control one. While, mean corpuscular hemoglobin con-

centration (MCHC) were declined in CCl₄ group and CCl₄+Vit D deficiency groups in comparison with the control one.

Our results showed a significant elevation in the total leukocytic and neutrophilic counts in the CCl₄ group and CCl₄+Vit D deficiency group comparing with the control one, while Vit D deficiency group showed no change. Meanwhile, neutrophil showed increase in CCl₄+Vit D deficiency group comparing with CCl₄ group. As well, lymphocytes was significantly decline in CCl₄+Vit D deficiency group and CCl₄ group in comparison with the

LIVER OXIDANT AND ANTIOXIDANT BIOMARKERS

The antioxidant biomarkers (GSH and SOD) were significantly reduced in CCl₄ group and CCl₄+Vit D deficiency group comparing with the control one. MDA levels were significantly increased in CCl₄ and CCl₄+Vit D deficiency groups in comparison with the control one (Figure 2).

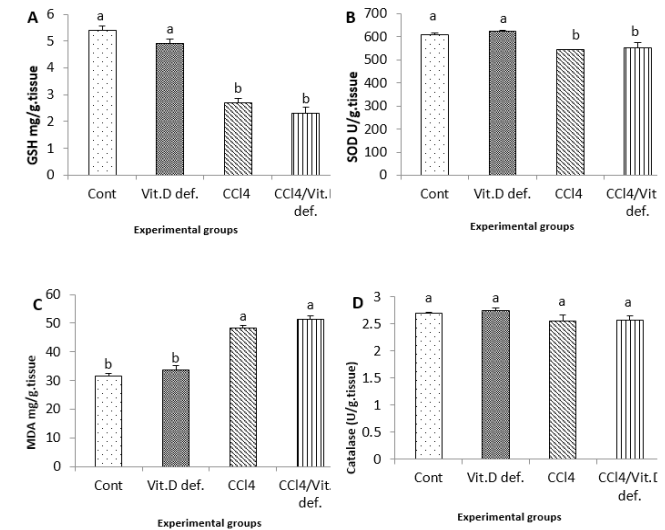


Figure 2: Hepatic levels of A, GSH; B, SOD; C, MDA; D, Catalase of male albino rat 6th week after induction of Vit D deficiency and liver necrosis (Mean± SE). Values with different superscript letters consider significance at (p< 0.05).

HISTOPATHOLOGICAL RESULTS

Liver displayed normal hepatic tissue with normal hepatocytes in control group (Figure 3A). In Vit D deficiency group, liver displayed severe congestion and hemorrhage in hepatic parenchyma (Figure 3B) while in CCl₄ group liver displayed scattered necrosis of hepatocytes (Figure 3C). As well, CCl₄ and CCl₄+Vit D deficiency groups liver displayed round cells infiltration in hepatic tissue and fibroblastic proliferation (Figure 3D).

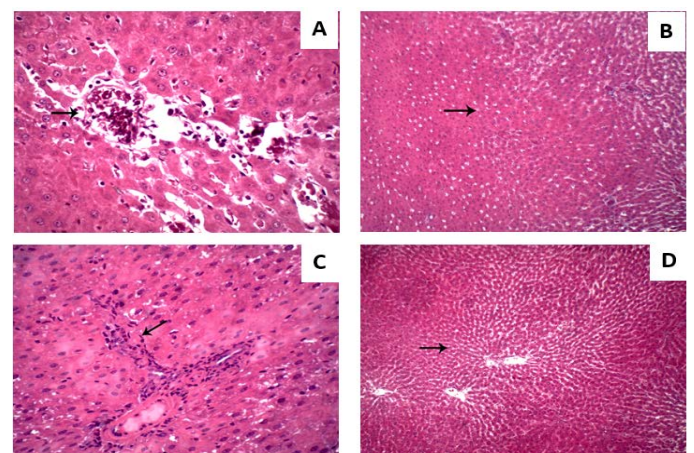


Figure 3: Hepatic micrograph (H&E, x400) of the different experimental groups. (A) control group; Liver displayed normal hepatic tissue with normal hepatocytes.

SERUM BIOCHEMICAL MARKER

Our results showed significant elevated in the serum activities of ALT, AST and ALP in the CCl₄ group and CCl₄+Vit D deficiency group compared to the control one. CCl₄ group and CCl₄+Vit D deficiency group showed a significant decrease in the serum total protein and globulin comparing with the control group, A/G ratio showed significantly increased level in CCl₄ group comparing with control group.

A significant elevation in total bilirubin, direct bilirubin, indirect bilirubin were observed in the CCl₄+Vit D deficiency group and CCl₄ group in comparison with control group, Meanwhile, they were insignificantly in Vit D group comparing with control group. Also CCl₄+Vit D deficiency showed significantly increased compared with CCl₄. Our results clarified that, the serum levels showed a significant increase in glucose and triglyceride levels in all groups when compared with control group or with each other, with the most significant increase was reported in CCl₄+Vit D deficiency group.

VITAMIN D, CALCIUM, AND PHOSPHORUS

Vitamins D levels were significantly declined in all experimental groups comparing with control one. Also vitamin D levels were significantly lower in CCl₄+Vit D deficiency group and Vit D deficiency group in compare with the CCl₄ group

Calcium level was decreased in Vit D deficiency group and CCl₄+Vit D deficiency group when compared with control group (Figure 1A). The serum phosphorus level in all investigated groups was insignificantly changed.

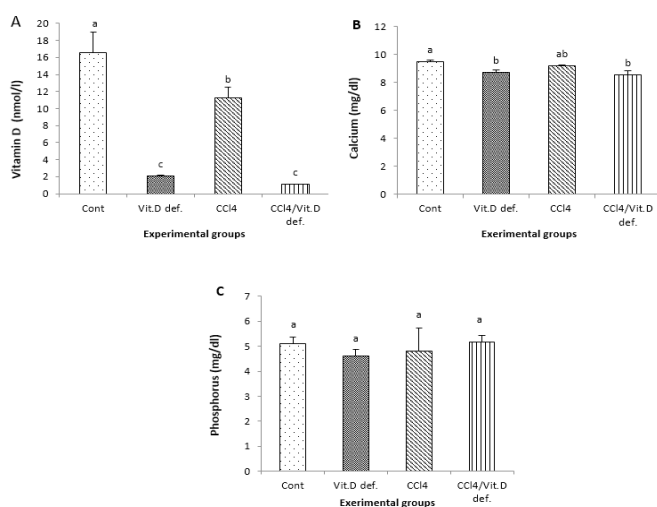


Figure 1: A, Vitamin D; B, Calcium; C, Phosphorus of male albino rat 6th week after induction of Vit D deficiency and liver necrosis (Mean± SE). Values with different superscript letters consider significance at (p< 0.05).

(B) Vit D deficiency group; Liver displayed hemorrhage in hepatic parenchyma. (C) CCl₄ group; Liver displayed scattered necrosis of hepatocytes. (D) CCl₄+Vit D deficiency group; Liver displayed fibroblastic proliferation.

DISCUSSION

Reactive oxygen species (ROS) due to direct exposure of the extracellular fluid to chemical assaults, coupled with their high oxygen content (Adaramoye and Akinloye, 2000). Also, vitamin D appears to be related to chronic disease prevention and erythropoiesis induction. The onset of CCl₄-induced liver fibrosis was preceded by RBCs-membrane alterations and the loss of membrane functional integrity. Erythrocytes are at high risk from damage by and differentiation in bone marrow cells (Arabi et al., 2020). It could stimulate erythrocyte precursor cell receptors, which promotes proliferation and maturation of erythroid progenitor cells (Icardi et al., 2013). In adults, a reverse relationship between anemia and vitamin D levels was indicated by several observational studies (Lucisano et al., 2014, Sim et al., 2010, Perlstein et al., 2011, Yoo and Cho, 2015). Also in agreements with our results, Marwah et al. (2012) showed that vitamin D deficiency correlated positively with MCV.

CCl₄ administration may gravely alter blood composition including erythrocytes and leukocytes (Abdullah, 2019). Similar findings reported that CCl₄ treated animals showed significantly decreased RBCs, hemoglobin, PCV, MCH, MCHC levels and lymphocyte counts and significantly increased MCV levels and total leukocytic and neutrophilic counts (Madthi et al., 2018, Abdullah, 2019). Beside the classic bone metabolism diseases, pathogenesis of several diseases associated with vitamin D deficiency may explained by studying the association between vitamin D, endothelial dysfunction and inflammation (Pludowski et al., 2013). In agreements with our findings, Akbas et al. (2016) support this association and they found that vitamin D deficiency was significantly associated with increased neutrophils and decreased lymphocytes as considered by increased platelet-to- and neutrophil-to- lymphocyte ratios.

In both acute and chronic liver diseases (CLD), hepatic necrosis is a common finding that always is followed by progressive fibrosis with persistence of the underlying cause. Thus during a patient's clinical evaluation, important information obtained from a liver biopsy is the pattern and extent of necrosis. This necrosis extent is a continuum, ranging from individual cell to massive hepatic necrosis. The pathologist role is to assess necrosis extent and pattern and other morphological changes, with the goal of suggesting one or more possible underlying causes

(Krishna, 2017).

From another hand, hepatic disease has been strongly associated with vitamin D deficiency, and the knockout of vitamin D receptor murine model has increased understanding of vitamin D's role in the liver (Keane et al., 2018). This vitamin deficiency is common in many CLD causes and has been related to the development of non-alcoholic fatty liver disease and chronic hepatitis C infection (Iruzubieta et al., 2014). Despite several impressive in vivo and in vitro studies using animals and human liver cell lines and the ease of access to vitamin D analogues and supplements, clinical data of the patient thus far remains inconclusive. Like other diseases, researches involving vitamin D interventions in hepatic disease have not yielded definitive findings and have tended to be small (Keane et al., 2018).

This study aimed to evaluate the association of vitamin D deficiency existence and the severity of liver inflammation induced by CCl₄ in albino rats. To achieve this, we compared between normal controls and rats with induced liver necrosis with and without vitamin D deficiency in biochemical, oxidative stress and antioxidant levels and liver histopathological findings.

In the present study, we used a model of CCl₄ for liver necrosis induction. CCl₄ hepatotoxic effect is related to short lived reactive metabolic intermediates and production of active free radicals under catalyzation through cytochrome P450. Continuous exposure to CCl₄ leads to compensatory cell proliferation and liver fibrosis. Consequently, repeated dosing of CCl₄ leads to progressively hepatic oxidative stress, injury morphological manifestation characterized by variation in hepatocyte nuclei size and worsening anisonucleosis (Uehara et al., 2014). There are many studies that used CCl₄ in liver necrosis or fibrosis induction (Eltahir et al., 2020; Karimi et al., 2020; Wu et al., 2020).

As illustrated in our study, compared with the control group, both CCl₄ and CCl₄+vitamin D deficiency groups were associated with significantly elevated activities of ALT, AST, ALP and total bilirubin. CCl₄ induced liver damage, serum bilirubin levels have been used to evaluate hepatic injury (Gressner et al., 2007). Bilirubin level was good indicator for pathological manifestation of jaundice, blood joundice caused by break down of red cells, impaired liver function of mechanical obstruction of bile duct (Bishayi et al., 2002). Although albumin was insignificantly changed in all groups compared to the control one, both CCl₄ and CCl₄+vitamin D deficiency groups showed significantly decreased total protein and globulin. Meanwhile, there were non-significant changes in vitamin D deficiency group.

Liver enzymes (ALT and AST) reflect the status of liver injury and are commonly elevated in patients with liver diseases. In conditions that affect primarily hepatocytes like toxin-induced liver damage and ischemic liver inflammation, marked elevation of these enzymes serum activity was observed. Also, serum bilirubin, albumin and total protein levels offer information regarding liver functional capacity (Hall and Cash, 2012). Beside its role as systemic inflammation monitor, reduced serum albumin might have a role in liver disease aggressiveness (Abdalla et al., 2013). Furthermore, ALP is a hydrolase enzyme present in all tissues entire body, but particularly concentrated in the placenta, bone, bile duct, kidney and liver. ALP is also have impact as poor predictor in liver disease outcome (Yu et al., 2011). Several studies reported that rats treated with CCl₄ were associated with changes in biomarkers of hepatic function which characterized by elevated transaminases (AST, ALT), bilirubin and ALP levels and decreased albumin and total protein levels (Xin et al., 2017; Moghazy and Elaidy, 2018).

Because the liver plays an important role in vitamin D pleiotropic functions and metabolism, the question is whether vitamin D deficiency is a contributor to liver dysfunction or a consequence of liver disease (Iruzubieta et al., 2014). However in CLD patients of varying etiologies, this vitamin deficiency has been associated with increased fibrosis severity (Targher et al., 2007). In agreements with our findings, Roth et al. (2012) showed that the existence of vitamin D deficiency affects the progression of liver fibrosis in nonalcoholic fatty liver disease with slightly (non-significant) effect on liver function tests.

Despite, serum phosphorus levels, our findings reported that animal groups with vitamin D insufficiency showed significant decrease in calcium serum levels. Since vitamin D primary function is it required to absorb calcium, then decreased vitamin D levels will causing less calcium absorption. In vitamin D deficiency, it is often claimed that intestinal calcium absorption efficiency is declined (Parfitt et al., 2004; Need et al., 2008). The significance of vitamin D extends is regulating the classical calcium-phosphorus-PTH axis domain (Andress, 2007), The bioactive forms of vitamin D is production in the kidney from inert precursors. So, chronic kidney disease is risk factor for development of vitamin D deficiency (Echida et al., 2012). A reduction in glomerular filtration rates (GFR) limits the delivery of 25(OH)D to the 1- α -hydroxylase enzyme in the proximal renal tubule, and so restricts the ability of the kidney to produce 1.25(OH)₂ D (Dusso and Tokumoto, 2011), In chronic kidney disease (CKD), levels of phosphaturic hormone FGF-23 increase, which is response to phosphate retention, which also suppresses production of 1.25(OH)₂ D (Liu et al., 2006).

Despite serum cholesterol, our results revealed that CCl₄ administration and vitamin D deficiency showed significant increase in blood triglycerides and glucose levels. It was reported that pathogenesis of CCl₄-induced hepatocyte injury was associated with the accumulation of triglycerides in hepatocytes and CCl₄ increased triglycerides and fatty acids synthesis and the rate of lipid esterification (Boll et al., 2001). Similar elevation in blood glucose was observed by many studies after CCl₄ exposure (Khan et al., 2015; Mahmoodzadeh et al., 2017). Many studies reported that vitamin D low levels were associated with high triglycerides, glucose and insulin levels particularly in postmenopausal women (Muñoz-Aguirre et al., 2015; Kwon and Lim, 2016). This vitamin deficiency has been linked to diabetes onset. In accordance with our findings, some studies reported that vitamin D supplementation reduces serum triglycerides levels and may prevent the onset of type 2 diabetes (Sergeev, 2016).

Our results clarified a significant reduction in activity of antioxidant parameters (GSH and SOD) and a significant elevation in the lipid peroxide (MDA) in both CCl₄ and CCl₄ + Vit D deficiency groups. Oxidative stress is the major cause for several degenerative disorders including hepatopathies. In the liver, cytochrome P450 system bio activation catabolizes CCl₄ to highly reactive metabolite, trichloromethyl radical (CCl₃[•]) (Koneri et al., 2008). Further, oxygen reacts with this radical to form the most toxic reactive trichloromethyl peroxy radical, which can bind to macromolecules and causing cell membrane damage and cell death. Oxidative stress occurred when there is an imbalance between ROS scavenging and production (Vidona and Wadioni, 2018). Thus, it is very clear that CCl₄ exposure decrease the activity of natural antioxidants. Also, lipid peroxidation (LPO) is important pathogenic event that damages bio-membranes. It is thought to be an oxidative stress consequence which occurs when the balance between antioxidant and prooxidant mechanism is impaired. CCl₄ exposure is associated with increased MDA, reliable LPO marker, in the kidney and the liver (Al-Yahya et al., 2013). Many studies reported such elevation in MDA levels and decreased in antioxidant levels including SOD and GSH after animal treatment with CCl₄ (Ritesh et al., 2015; Aleissa et al., 2020).

Increasing data demonstrate that vitamin D has an antioxidant activity (Velimirović et al., 2018). However, in accordance with our results, the role of vitamin D as an antioxidant has not been clearly reported (Afshari et al., 2015). Other studies reported that vitamin D deficiency affects the antioxidant status and its supplementation may be act as enhancer for SOD and catalase activation (Javanbakht et al., 2010). Recently in chronic alcohol-induced mice with liver injury, Hu et al. (2020) found that

vitamin D deficiency may aggravates liver inflammation and oxidative stress during.

In contrast to the control group that displayed normal hepatocytes, hepatic tissue, our results showed that vitamin D deficiency displayed severe congestion and hemorrhage in hepatic and renal parenchyma. While in CCl₄ group liver displayed scattered necrosis of hepatocytes and kidney displayed renal tubular epithelium vacuolation and severe renal glomeruli congestion and proliferation. As well, coexistence of vitamin D deficiency with liver necrosis aggravates these outcomes and displayed round cells infiltration in hepatic tissue and fibroblastic proliferation and massive hemorrhage replacing renal parenchyma.

Due to their hepatic toxicological effect, many studies reported that CCl₄ animals models showed sever hepatic damage that presented by histological findings. For example, [Xin et al. \(2017\)](#) histologically found that the liver lesions of CCl₄-treated animals exhibited necrosis with multifocal distribution and invasive growth and arose within diffuse dysplastic areas. Also, [Zayed et al. \(2019\)](#) found that DEN/ CCl₄ co-administration caused liver neoplasia with well differentiated tumor cells, hepatocytic nuclei karyomegaly, oval cells proliferation, sporadic hepatocytes necrosis, hepatocytes cytoplasmic vacuolization and inflammatory infiltration. Similarly, many other studies reported liver specimens pathological and histological alters along with significant collagen fiber content increase induced by these chemicals of showed that CCl₄ caused patchy and variable changes in the liver tissue ([El Sayed et al., 2019](#)). In human non-alcoholic fatty liver disease (NAFLD), in agreements with our results, [Targher et al. \(2007\)](#) showed that patients with NAFLD have a marked decrease in vitamin D levels which is closely associated with histopathological features of NAFLD.

CONCLUSION

In summary, our findings revealed that the co-excitance of vitamin D deficiency with liver necrosis may cause disease progression and aggravates hepatic fibrosis. This was confirmed by our findings of hematological, biochemical, oxidative stress assessment and histopathological studies. However, our results highlighted the value of vitamin D level measurements and control in liver disease to prevent disease progression.

ACKNOWLEDGEMENTS

All authors are very grateful to all members of the Clinical Pathology Department for their encouragement and support during this study.

The authors declare no conflict of interests

LIST OF ABBREVIATIONS

AST: Aspartate transferase, ALT: Alanine transferase, ALP: Alkaline phosphatase, CAT: Catalase, GSH: Reduced glutathione, MDA: Malondialdehyde, SOD: Superoxide dismutase,

AUTHORS CONTRIBUTION

N.A.E.; methodology, formal analysis, data curation, writing original draft, review, and editing. G.E.E., F.M.A., and E.F.R.; conceptualization, validation, visualization, editing final draft and supervision. M.S.Y.; preparation of diet, writing, review and data curation . E.F.R.; prepared the manuscript for publication. All authors read and approved the final manuscript.

REFERENCES

- Abdalla OA, Risha EF, Elshopekey GE (2013). Hepatoprotective and antioxidant effects of artichoke against carbon tetrachloride-toxicity in rats. *Life Sci. J.* 10: 1436-1444.
- Abdullah IH (2019). Effect of Carrot Juice on Some Blood Parameters in CCl₄ intoxicated rabbits. *Egyptian Acad. J. Biolog. Sci.* 11: 53-59. <https://doi.org/10.21608/eajbsc.2019.53474>
- Adaramoye OA, Akinloye O (2000). Possible protective effect of kolaviron on CCl₄-induced erythrocyte damage in rats. *Biosci. Rep.* 20: 259-264. <https://doi.org/10.1023/A:1026488823157>
- Afshari L, Amani R, Soltani F, Haghighizadeh MH, Afsharmanesh MR (2015). The relation between serum Vitamin D levels and body antioxidant status in ischemic stroke patients: A case-control study. *Adv. Biomed. Res.* 4: 213-213.
- Akbas EM, Gungor A, Ozcicek A, Akbas N, Askin S, Polat M (2016). Vitamin D and inflammation: evaluation with neutrophil-to-lymphocyte ratio and platelet-to-lymphocyte ratio. *Archiv. Med. Sci. AMS.* 12: 721-727. <https://doi.org/10.5114/aoms.2015.50625>
- Aleissa MS, Alkahtani S, Abd Eldaim MA, Ahmed AM, Bungäu SG, Almutairi B, Bin-Jumah M, AlKahtane AA, Alyousif MS, Abdel-Daim MM (2020). Fucoidan ameliorates oxidative stress, inflammation, DNA damage, and hepatorenal injuries in diabetic rats intoxicated with aflatoxin B1. *Oxid. Med. Cell. Longev.* 2020: 1-9.
- Al-Yahya M, Mothana R, Al-Said M, Al-Dosari M, Al-Musayeib N, Al-Sohaibani M, Parvez MK, Rafatullah S (2013). Attenuation of CCl₄-Induced Oxidative Stress and Hepatonephrotoxicity by Saudi Sidr Honey in Rats. *Evid. Based Complement. Alternat. Med.* 569037. <https://doi.org/10.1155/2013/569037>
- Andress D (2007). Nonclassical aspects of differential vitamin D receptor activation. *Drugs.* 67: 1999-2012. <https://doi.org/10.2165/00003495-200767140-00003>
- Arabi SM, Ranjbar G, Bahrami LS, Vafa M, Norouzy A (2020).

- The effect of vitamin D supplementation on hemoglobin concentration: a systematic review and meta-analysis. *Nutr. J.* 19: 11. <https://doi.org/10.1186/s12937-020-0526-3>
- Autier P (2007). Vitamin D Supplementation and Total Mortality_{title>A Meta-analysis of Randomized Controlled Trials}. *Archiv. Inter. Med.* 167: 1730 <https://doi.org/10.1001/archinte.167.16.1730>.
 - Bancroft JP, Stevens A, Turner DR (1990). *Theory and practice of histological techniques*, 3rd ed, Edinburgh, London.
 - Bhan I, Powe CE, Berg AH, Ankers E, Wenger JB, Karumanchi SA, Thadhani RI (2012). Bioavailable vitamin D is more tightly linked to mineral metabolism than total vitamin D in incident hemodialysis patients. *Kidney Int.* 82: 84-89. <https://doi.org/10.1038/ki.2012.19>
 - Bishayi B, Roychowdhury S, Ghosh S, Sengupta M (2002). Hepatoprotective and immunomodulatory properties of *Tinospora cordifolia* in CCl₄ intoxicated mature albino rats. *J. Toxicolog. Sci.* 27 139-146. <https://doi.org/10.2131/jts.27.139>
 - Boll M, Weber LW, Becker E, Stampfl A (2001). Pathogenesis of carbon tetrachloride-induced hepatocyte injury bioactivation of CCl₄ by cytochrome P450 and effects on lipid homeostasis. *Zeitschrift für Naturforschung C.* 56: 111-121.
 - Chung H, Hong DP, Jung Jy, Kim HJ, Jang KS, Sheen YY, Ahn JI, Lee YS, Kong G (2005). Comprehensive analysis of differential gene expression profiles on carbon tetrachloride-induced rat liver injury and regeneration. *Toxicol. Appl. Pharmacol.* 206: 27-42. <https://doi.org/10.1016/j.taap.2004.11.004>
 - Dusso AS, Tokumoto M (2011). Defective renal maintenance of the vitamin D endocrine system impairs vitamin D renoprotection: a downward spiral in kidney disease. *Kidney Int.* 79: 715-729. <https://doi.org/10.1038/ki.2010.543>
 - Echida Y, Mochizuki T, Uchida K, Tsuchiya K, Nitta K (2012). Risk factors for vitamin D deficiency in patients with chronic kidney disease. *Inter. Med.* 51: 845-850. <https://doi.org/10.2169/internalmedicine.51.6897>
 - Elaidy SM, Moghazy A, Mohamed K (2017). Evaluation of the therapeutic effects of polyvinylpyrrolidone-capped silver nanoparticles on the diethylnitrosamine/carbon tetrachloride-induced hepatocellular carcinoma in rats. *Egy. J. Basic. Clin. Pharmacol.* 7(2): 9-24.
 - El Sayed Helsa, Morsy Lels, Abo Emar TM, Galhom RA (2019). Effect of Carbon Tetrachloride (CCl₄) on Liver in Adult Albino Rats: Histological study. *Egypt. J. Hosp. Med.* 76: 4254-4261.
 - Eltahir HM, Fawzy MA, Mohamed EM, Alrehany MA, Shehata AM, Abouzied MM (2020). Antioxidant, anti-inflammatory and anti-fibrotic effects of *Boswellia serrate* gum resin in CCl₄-induced hepatotoxicity. *Exp. Ther. Med.* 19: 1313-1321.
 - Feldman BF Zinkl JG, Jain NC (2000). *Schalm's veterinary hematology*.
 - Goodla L, Manubolu M, Pathakoti K, Jayakumar T, Sheu JR, Fraker M, Tchounwou PB, Poondamalli PR (2019). Protective effects of *ammannia baccifera* against CCl₄-induced oxidative stress in rats. *Int. J. Environmen. Res. Pub. Health.* 16: 1440. <https://doi.org/10.3390/ijerph16081440>
 - Gressner OA, Weiskirchen R, Gressner AM (2007). Biomarkers of liver fibrosis: clinical translation of molecular pathogenesis or based on liver-dependent malfunction tests. *Clin. Chimica Acta.* 381: 107-113. <https://doi.org/10.1016/j>
 - Hall P, Cash J (2012). What is the real function of the liver 'function' tests? *Ulster Med. J.* 81: 30-36.
 - Holick MF (2006). March. High prevalence of vitamin D inadequacy and implications for health. In *Mayo Clin. Proceed.* 81(3): 353-373).
 - Hu CQ, Bo QL, Chu LL, Hu YD, Fu L, Wang GX, Lu Y, Liu XJ Wang H, Xu DX (2020). Vitamin D Deficiency Aggravates Hepatic Oxidative Stress and Inflammation during Chronic Alcohol-Induced Liver Injury in Mice. *Oxidat. Med. Cellul. Longevit.* 5715893-5715893. <https://doi.org/10.1155/2020/5715893>
 - Icardi A, Paoletti E, De Nicola L, Mazzaferro S, Russo R, Cozzolino M (2013). Renal anaemia and EPO hyporesponsiveness associated with vitamin D deficiency: the potential role of inflammation. *Nephrol. Dial. Transplant.* 28: 1672-9. <https://doi.org/10.1093/ndt/gft021>
 - Iruzubieta p, terán á, crespo j, fábrega e (2014). Vitamin D deficiency in chronic liver disease. *World J. Hepatol.* 6: 901-915. <https://doi.org/10.4254/wjh.v6.i12.901>
 - Javanbakht M, Keshavarz S, Mirshafiey A, Djalali M, Siassi F, Eshraghian M, Firooz A, Seirafi H, Ehsani A, Chamari M (2010). The effects of vitamins e and d supplementation on erythrocyte superoxide dismutase and catalase in atopic dermatitis. *Iran J. Pub. Health.* 39: 57-63.
 - Jeong TB, Kwon D, Son SW, Kim SH, Lee YH, Seo MS, Kim KS, Jung YS (2020). Weaning Mice and Adult Mice Exhibit Differential Carbon Tetrachloride-Induced Acute Hepatotoxicity. *Antioxidants.* 9: 201. <https://doi.org/10.3390/antiox9030201>
 - Karimi J, Mohammadalipour A, Sheikh N, Khodadadi I, Hashemnia M, Goudarzi F, Khanjarsim V, Solgi G, Hajilooi M, Bahabadi M (2020). Protective effects of combined Losartan and Nilotinib on carbon tetrachloride (CCl₄)-induced liver fibrosis in rats. *Drug. Chem. Toxicol.* 43: 468-478.
 - Keane JT, Elangovan H, Stokes RA, Gunton JE (2018). Vitamin D and the Liver—Correlation or Cause? *Nutrients.* 10: 49. <https://doi.org/10.3390/nu100404966>
 - Khan RA, Khan MR, Sahreen S, Ahmed M, Shah NA (2015). Carbon tetrachloride-induced lipid peroxidation and hyperglycemia in rat: a novel study. *Toxicol. Ind. Health.* 31: 546-553.
 - Koneri R, Balaraman R, Firdous KM, Kumar M (2008). Hepatoprotective effects of *Momordica Cymbalaria* Fenzl. against carbon tetrachloride induced hepatic injury in rats. *Pharmacol. Online.* 1: 365-374.
 - Krishna M (2017). Patterns of necrosis in liver disease. *Clin Liver Dis (Hoboken).* 10: 53-56. <https://doi.org/10.1002/cld.653>
 - Kwon HN, Lim H (2016). Relationship between serum vitamin D status and metabolic risk factors among Korean adults with prediabetes. *PLoS. One.* 11: 1-11.
 - Liu S, Tang W, Zhou J, Stubbs JR, Luo Q, Pi M, Quarles LD (2006). Fibroblast growth factor 23 is a counter-regulatory phosphaturic hormone for vitamin D. *J. American Soci. Nephrol.* 17: 1305-1315. <https://doi.org/10.1681/ASN.2005111185>
 - Lucisano S, Di Mauro E, Montalto G, Cernaro V, Buemi M, Santoro D (2014). Vitamin D and anemia. *J. Ren. Nutr.* 24: 61-2. <https://doi.org/10.1053/j.jrn.2013.09.004>
 - Madthi AS, Al-Diwan MA, Al-Jadaan SAN (2018). Hematological profile of rats treated with Quercetin

- derivative against carbon tetrachloride (CCL4) toxicity. *Basrah J. Vet. Res.* 17: 70-84.
- Mahmood Zadeh Y, Mazani M, Rezagholizadeh L (2017). Hepatoprotective effect of methanolic *Tanacetum parthenium* extract on CCL4-induced liver damage in rats. *Toxicol. Rep.* 4: 455-462.
 - Mahmoud R, Elshopakey G, Awadin W (2020). Effects of feeding diets supplemented with different levels of L-carnitine on growth performance, serum metabolites, histopathological changes in growing Japanese quails. *Int. J. Vet. Sci.* 9: 16-23.
 - Marwah S, Walls A, Blann AD (2012). Relationship between vitamin D and red blood cell indices in South Asians and White Europeans. *Br. J. Biomed. Sci.* 69: 182-5. <https://doi.org/10.1080/09674845.2012.12069151>
 - Muñoz-Aguirre P, Flores M, Macias N, Quezada AD, Denova-Gutiérrez E, Salmerón J (2015). The effect of vitamin D supplementation on serum lipids in postmenopausal women with diabetes: a randomized controlled trial. *Clin. Nutr.* 34: 799-804.
 - Nair R, Maseeh A (2012). Vitamin D: The “sunshine” vitamin. *J. Pharmacol. Pharmacotherapeut.* 3: 118-126.
 - Natsume M, Tsuji H, Harada A, Akiyama M, Yano T, Ishikura H, Nakanishi I, Matsushima K, Kaneko SI, Mukaida N (1999). Attenuated liver fibrosis and depressed serum albumin levels in carbon tetrachloride-treated IL-6-deficient mice. *J. Leukocyte Biol.*, 66: 601-608. <https://doi.org/10.1002/jlb.66.4.601>
 - Need AG, O’Loughlin PD, Morris HA, Coates PS, Horowitz M, Nordin BC (2008). Vitamin D metabolites and calcium absorption in severe vitamin D deficiency. *J. Bone. Miner. Res.* 23: 1859-1863.
 - Norušis MJ (2006). SPSS 14.0 guide to data analysis, Prentice Hall Upper Saddle River, NJ.
 - Osama A, Engy R, Gehad E (2014). Immunomodulatory effect of artichoke (*Cynara scolymus*) on carbon tetrachloride induced immunosuppression in rats. *Ann Vet. Anim. Sci.* 1: 66-76.
 - Parfitt A, Qiu S, Rao D (2004). The mineralization index—a new approach to the histomorphometric appraisal of osteomalacia. *Bone.* 35: 320-325.
 - Perlstein TS, Pande R, Berliner N, Vanasse GJ (2011). Prevalence of 25-hydroxyvitamin D deficiency in subgroups of elderly persons with anemia: association with anemia of inflammation. *Blood.* 117: 2800-6. <https://doi.org/10.1182/blood-2010-09-309708>
 - Piudowski P, Karczmarewicz E, Bayer M, Carter G, Chlebna-Sokół D, Czech-Kowalska J, Dębski R, Decsi T, Dobrzańska A, Franek E (2013). Practical guidelines for the supplementation of vitamin D and the treatment of deficits in Central Europe—recommended vitamin D intakes in the general population and groups at risk of vitamin D deficiency. *Endokrynologia Polska.* 64: 319-327.
 - Ritesh K, Suganya A, Dileepkumar H, Rajashekar Y, Shivanandappa T (2015). A single acute hepatotoxic dose of CCl₄ causes oxidative stress in the rat brain. *Toxicol. Rep.* 2: 891-895.
 - Roth CL, Elfers CT, Figlewicz DP, Melhorn SJ, Morton GJ, Hoofnagle A, Yeh MM, Nelson JE, Kowdley KV (2012). Vitamin D deficiency in obese rats exacerbates nonalcoholic fatty liver disease and increases hepatic resistin and Toll-like receptor activation. *Hepatology.* 55: 1103-1111.
 - Saggese G, Vierucci F, Boot AM, Czech-Kowalska J, Weber G, Camargo CA, MALLETT E, Fanos M, Shaw NJ, Holick MF (2015). Vitamin D in childhood and adolescence: an expert position statement. *Euro. J. Pediatr.* 174: 565-576. <https://doi.org/10.1007/s00431-015-2524-6>
 - Sergeev IN (2016). 1, 25-Dihydroxyvitamin D3 and type 2 diabetes: Ca²⁺-dependent molecular mechanisms and the role of vitamin D status. *Horm. Mol. Biol. Clin. Investig.* 26: 61-65.
 - Sim JJ, Lac PT, Liu IL, Meguerditchian SO, Kumar VA, Kujubu DA, Rasgon SA (2010). Vitamin D deficiency and anemia: a cross-sectional study. *Ann Hematol.* 89: 447-52. <https://doi.org/10.1007/s00277-009-0850-3>
 - Su LJ, Zhang JH, Gomez H, Murugan R, Hong X, Xu D, Jiang F, Peng ZY (2019). Reactive Oxygen Species-Induced Lipid Peroxidation in Apoptosis, Autophagy, and Ferroptosis. *Oxidat. Med. Cellul. Longevit.* 1-13. <https://doi.org/10.1155/2019/5080843>
 - Targher G, Bertolini L, Scala L, Cigolini M, Zenari L, Falezza G, Arcaro G (2007). Associations between serum 25-hydroxyvitamin D3 concentrations and liver histology in patients with non-alcoholic fatty liver disease. *Nutr. Metab. Cardiovasc. Dis.* 17: 517-524.
 - Tietz NW (1990). Clinical guide to laboratory tests, WB Saunders company, Philadelphia, USA.
 - Uehara T, Pogribny IP, Rusyn I (2014). The DEN and CCl₄-induced mouse model of fibrosis and inflammation-associated hepatocellular carcinoma. *Curr. Protoc. Pharmacol.* 66: 14.30. 1-14.30. 10.
 - Velimirović M, Jevtić Dožudić G, Selaković V, Stojković T, Puškaš N, Zaletel I, Živković M, Dragutinović V, Nikolić T, Jelenković A (2018). Effects of vitamin D3 on the NADPH oxidase and matrix metalloproteinase 9 in an animal model of global cerebral ischemia. *J. Oxidat. Med.* 1-14. <https://doi.org/10.1155/2018/3273654>
 - Vidona W, Wadioni A (2018). Assessment of liver histomorphology and curative effect of chloroform extract of *Telfairia occidentalis* seed on carbon tetrachloride (CCl₄) induced liver toxicity in Wistar rats. *J. Biomedical. Sci.* 7: 4-13.
 - Wu H, Chen G, Wang J, Deng M, Yuan F, Gong J (2020). TIM-4 interference in Kupffer cells against CCL4-induced liver fibrosis by mediating Akt1/Mitophagy signalling pathway. *Cell. Prolifer.* 53: 1-12.
 - Xin B, Cui Y, Wang Y, Wang L, Yin J, Zhang L, Pang H, Zhang H, Wang RA (2017). Combined use of alcohol in conventional chemical-induced mouse liver cancer model improves the simulation of clinical characteristics of human hepatocellular carcinoma. *Oncology letters.* 14: 4722-4728. <https://doi.org/10.3892/ol.2017.6800>
 - Yoo EH, Cho HJ (2015). Prevalence of 25-hydroxyvitamin D deficiency in Korean patients with anemia. *J. Clin. Lab Anal.* 29: 129-34. <https://doi.org/10.1002/jcla.21740>
 - Young DS (2001). Effects of disease on clinical lab tests, 4th ed AACC.
 - Yu M-C, Chan K-M, Lee C-F, Lee Y-S, Eldeen FZ, Chou H-S, Lee W-C, Chen M-F (2011). Alkaline phosphatase: does it have a role in predicting hepatocellular carcinoma recurrence? *J. Gastrointest. Surg.* 15: 1440-1449.
 - Zayed MN, Aly HF, Moneim El-Mezayen HA, El-Salamony HE (2019). Effect of co-administration of Bee honey and some chemotherapeutic drugs on dissemination of hepatocellular carcinoma in rats. *Toxicol. Rep.* 6: 875-888. <https://doi.org/10.1016/j.toxrep.2019.08.007>