



## Research Article

### Prevalence of *Haemoproteus Sp* in Domestic Pigeon at Chittagong and Khulna District in Bangladesh

Muhammad Shafiqul Islam<sup>1\*</sup>, Muhammad Abdul Alim<sup>1</sup>, Shubhagata Das<sup>1</sup>, Kazal Krishna Ghosh<sup>2</sup>, Shahnaj Pervin<sup>1</sup>, Afroza Lipi<sup>2</sup>, AMAM Zonaed Siddiki<sup>1</sup>, Muhammad Masuduzzaman<sup>1</sup>, Muhammad Alamgir Hossain<sup>1</sup>

<sup>1</sup>Department of Pathology and Parasitology, Chittagong Veterinary and Animal Sciences University, Khulshi, Chittagong-4225; <sup>2</sup> Department of Microbiology, Chittagong Veterinary and Animal Sciences University, Khulshi, Chittagong-4225  
\*Corresponding author: si.mamun@gmail.com

#### ARTICLE HISTORY

Received: 2014-02-04  
Revised: 2014-04-14  
Accepted: 2014-04-23

#### ABSTRACT

A study was carried out to determine the prevalence of *Haemoproteus sp* in domestic pigeon at Chittagong and Khulna district in Bangladesh. A total of 213 blood samples were collected from six different locations in Chittagong (Foy's lake, Bibrhat, Zhaotola) and Khulna district (Banorgati, Sheikhpara, Goborchaka). Blood smears were stained with geimsa and examined under microscope using immersion oil. Mature and immature stages of *Haemoproteus* gametocytes were found in 43.63% and 58.25% in Chittagong and Khulna respectively. The prevalence was almost similar in the areas of Khulna district (55.55 – 62.86%), whereas, a fluctuation observed in Chittagong district from 33.33 to 59.52%. Finally, we recommended further extensive studies by molecular characterization which will help to make a parasitic lineage.

**Key Words:** *Haemoproteus sp*, Prevalence, Microscopy, Gametocytes

All copyrights reserved to Nexus® academic publishers

ARTICLE CITATION: Islam MS, Alim MA, Das S, Ghosh KK, Pervin S, Lipi A, Siddiki AZ, Masuduzzaman M, Hossain MA (2014). Prevalence of *haemoproteus sp* in domestic pigeon at Chittagong and Khulna district in Bangladesh. J. Adv. Parasitol. 1 (2): 24 – 26..

#### INTRODUCTION

Pigeons are used as pets, cultural and religious symbols. They also have value as a source of food, hobby and experimental purposes (Sari et al., 2008). Pigeons are affected with several health problems, whereas parasite infections play a major role. Parasitic infection can lead to retarded growth, low egg production and susceptibility to other infections in birds (Dranzoa, 1999).

However, parasitic protozoa *Haemoproteus sp* are widely distributed in tropical and subtropical regions (Adriano and Cordeiro, 2001). In a taxonomic review of the haemoproteids parasites of columbids, only *H. columbae* and *H. sacharoyi* are valid species (Bennett and Peirce, 1990). Among which *H. columbae* infects most commonly in pigeon and doves and are transmitted by blood-sucking louse fly *Pseudolynchia canariensis*, which is a proven vector of *H. columbae* (Bennett et al., 1993). Based on the morphological features of the blood stages over 140 species of avian *Haemoproteus* have been described (Bishop and Bennett, 1992). Some of which are responsible for severe pathology in birds and in pigeons

only cause's disease in stressed condition (Zinkl, 1986). Many recent studies have been recorded on avian blood parasites in different areas of the world (Bensch et al., 2000; Ricklefs et al., 2005). Based on microscopic examination the prevalence of *Haemoproteus sp* was recorded 20% in Mymensingh district in Bangladesh (Dey et al., 2010). However, there is no study regarding *Haemoproteus sp* infection in Chittagong and Khulna region, that's why, the present study was performed to detect the *Haemoproteus sp* and address the pigeon farmers about its amplitude.

#### Materials and Methods

##### Study Area

The study was carried out from April 2012 to may 2013 involving randomly selected 110 and 103 domestic pigeons (*Columba livia*) from different location at Chittagong (Bibirhat, Foy's lake and Zhaotola) and Khulna (Sheikhpara, Shib bari and Gobor chaka) respectively.

Table 1: Overall percentage of *Haemoproteus columbae* in Chittagong and Khulna city

Area	Location of farms	No. of pigeon	Hemoproteus (+ve) (No. of pigeon)	Percentage Positive	Overall % positive
Chittagong Metropolitan area	Sholoshohor	35	12	34.26	46.60
	Foy's lake	42	25	59.52	
	Zhaotola	33	11	33.33	
Khulna city	Sheikhpara	32	18	56.25	58.25
	Shib bari	35	22	62.86	
	Gobor chaka	36	20	55.55	

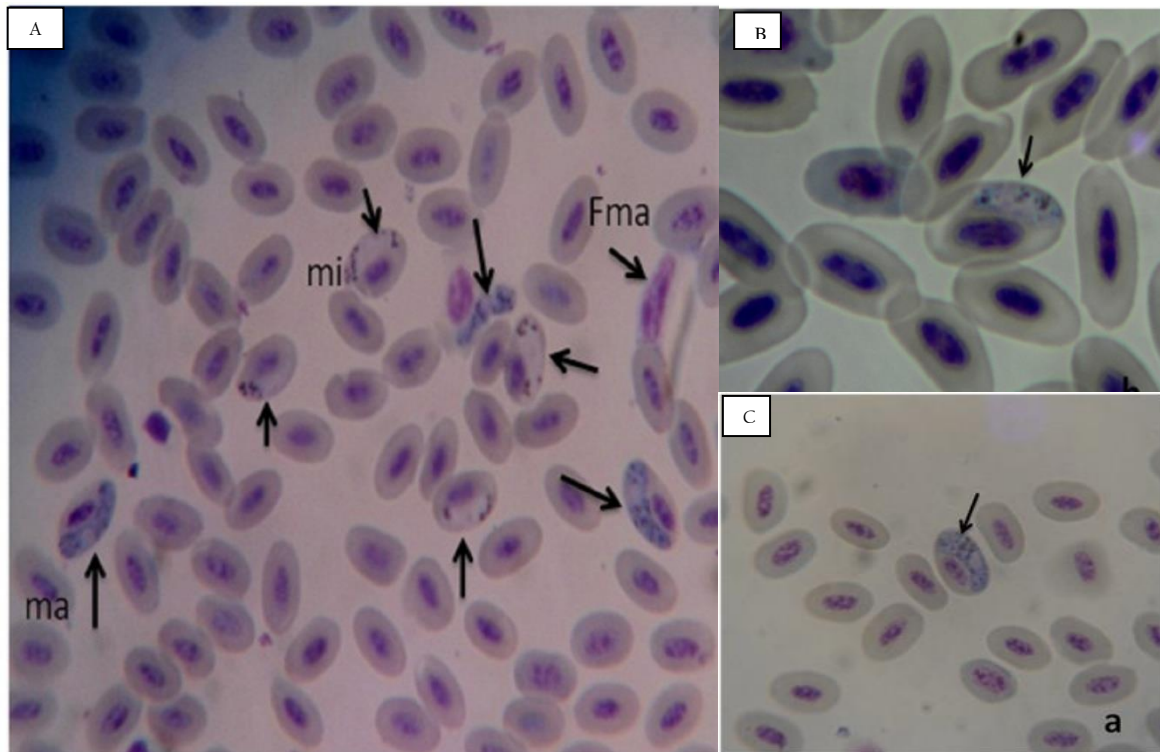
### Sample Collection and Examination

Blood samples for the preparation of blood smears were obtained from a brachial vein and the pigeon then tagged and released. The air-dried blood smears were subsequently fixed in absolute methanol 3–5 minutes and later stained with Giemsa's with phosphate buffer (pH 7.4) in the ratio of 1:7 for 30 minutes. All dried smears were examined under light microscopy for the detection of blood protozoa and identified according to Soulsby (1982).

### RESULTS AND DISCUSSIONS

All samples were microscopically examined and gametocytes of *Haemoproteus sp.* were seen within red blood cells. Diagnostic characters included the elongated,

crescent-shaped forms of the gametocyte, its nucleus size and position in the cell (Picture 1–A). Mature macrogametocytes were circumnuclear and lightly staining blue with Giemsa; refractile granules were found in various sizes, generally moderately large and ovoid, occasionally smaller (Picture 1–C). Whereas, microgametocyte stained pale pink including pigments granule occupied in polar position (Picture 1–B). The characters of macro and micro gametocytes of the present study were in line with Youssefi and Rahimi (2011). Furthermore, Mushi et al. (1999) found *H. columbae* gamets (immature and mature gametocytes) in blood samples of 75% pigeons through microscopic examination.



Picture 1: A. Macrogametocyte (ma), Microgametocyte (mi) and free gametocyte (Fma) in the blood picture that are released from the erythrocyte B. Microgametocytes. C. Macrogametocytes.

In the current study, out of 110 and 103 samples, 48 (46.60%) and 60 (58.25%) were found positive in Chittagong and Khulna district respectively (Table 1). In contrary, studies regarding *Haemoproteus* infection conducted at Mymensingh district in Bangladesh (Dey et al., 2010), Bursa region (Senlik, 2005) and Madagascar (Raharimanga et al., 2002) revealed prevalence rate ranges from 19–21%. However, the present study was corresponding with Dranzoa et al., (1999); Orajaka and Nweze (1991) who reported that 76.5% and 37.5% pigeons are positive for *Haemoproteus columbae* respectively in Uganda and Nigeria. Infection load was highest in Khulna City (55.55–62.86%) in comparison with Chittagong district and the infection was lowered in two areas of Chittagong district (Zhaotola 33.33% and Sholoshohor 34.26%) in *Columba livia*. These differences might be due to climatic

condition, population density and husbandry practices of pigeon.

In the present study, samples from healthy pigeons exhibited the high infection load of *Haemoproteus sp.* This high prevalence could be attributed to the presence of blood sucking vector flies *Pseudolynchia canariensis* (Bennett et al., 1993). Dey et al., (2010) found utmost association of *Pseudolynchia canariensis* (90%) with the developmental stage of *Haemoproteus spp* in Mymensing, Bangladesh.

### CONCLUSION

In conclusion, our study indicated that more studies are required owing to different prevalence rates in different parts of Bangladesh. *Haemoproteus sp* should therefore be considered a economic threat for pigeon farmers' although there is no published data available in our country.

## REFERENCES

- Adriano AE, Cordeiro SN (2001). Prevalence and Intensity of *Haemoproteus columbae* In three Species of Wild Doves from Brazil. Mem. Inst. Oswaldo. Cruz, Rio de Janeiro, Vol. 96 (2): 175–178.
- Bensch S, Stjernman M, Hasselquist D, Ostman O, Hansson B, Westerdahl H, Pinheiro RT (2000). Host specificity in avian blood parasites: a study of *Plasmodium* and *Haemoproteus* mitochondrial DNA amplified from birds. Proc. R. Soc. Lond. B. 267: 1583–1589.
- Bennett GF, Peirce MA (1990). The haemoproteid parasites of the pigeons and doves (family Columbidae). J. Nat. Hist. 24: 311–325.
- Bennett GF, Pierce MA, Ashford RW (1993). Avian haematozoa: Mortality and pathogenicity. J. Natur. Histo. 27: 993–1001.
- Bishop MA, Bennett GF (1992). Host-parasite catalogue of the avian haematozoa: Supplement 1 and Bibliography of the avian blood-inhabiting haematozoa: Supplement 2. Occasional Papers in Biology. Memorial University Newfoundland, 15, 1–244.
- Dey AR, Begum N, Paul SC, Noor M, Islam K (2010). Prevalence and pathology of blood protozoa in pigeons reared at Mymensingh district, Bangladesh. Int. J. Bio. Res. 2 (12): 25–29.
- Dranzoa C, Ocaido M, Katete P (1999). The ecto- gastro-intestinal and haemo-parasites of live pigeons (*Columba livia*) in Kampala, Uganda. Avi. Pathol. 28(2): 119–124.
- Mushi EZ, Binta MG, Chabo RG, Mathaio M, Ndebele RT (1999). *Haemoproteus Columbae* in domestic pigeons in Sebele, Gaborone, Botswana. Ond. J. Vet. Res. 66: 29–32.
- Orajaka LJ, Nweze LC (1991). Prevalence of blood protozoan parasites of avian species in Nsukka area of Anambra State, Nigeria. Beitr. Trop. Landwirtschaft. Veterinarmed. 29(1): 91–95.
- Raharimanga V, Soula F, Raheiralaio MJ, Goodman SM, Sadonès H, Tall A, Randrianarivojosia M, Raharimalala L, Duchemin JB, Ariey F, Robert V (2002). Hemoparasites in wild birds in Madagascar. Archi. Insti. Paste. Madaga. 68(1–2): 90–94.
- Ricklefs RE, Fallon SM, Latta SC, Swanson BL, Bermingham E (2005). Migrants and their parasites: a bridge between two worlds, In: Birds of Two Worlds: The Ecology and Evolution of Migrants, The Johns Hopkins University Press, Baltimore, 210–221.
- Sari B, Karatepe B, Karatepe M, Kara M (2008). Parasites of domestic pigeon (*Columba livia domestica*) and wild (*Columba livia livia*) pigeons in Niğde, Turkey. Bull. Vet. Inst. Pulawy. 52: 551–554.
- Senlik B, Gulegen E, Akyol V (2005). Prevalence and intensity of *Haemoproteus columbae* in domestic pigeons. Ind. Vet. J. 82(9): 998–999.
- Soulsby EJJ (1982). Arthropods and Protozoa of Domesticated Animals (7<sup>th</sup> Ed), ELBS and Bailliere Tindall, London, 700–706.
- Youssefi MR, Rahimi MT (2011). *Haemoproteus Columbae* in *Columba livia domestica* of Three Areas in Iran in 2010. Glob. Vet. 7 (6): 593–595.
- Zinkl JG (1986). Avian Haematology, in Schalm's Veterinary Haematology (4<sup>th</sup> Ed), Philadelphia: Lea & Febiger, 256–273.