

Research Article

Gill Disease Caused by *Thelohanellus bifurcata* Basu and Haldar, 1999 a Pathogenic Myxozoan Parasite in Cultured Indian Carp, *Labeo rohita* (Hamilton, 1822) in Punjab, India

Harpreet Kaur*, Anu Katoch

Department of Zoology and Environmental Sciences, Punjabi University, Patiala -147002, India
*Corresponding author: harpreetbimbra@gmail.com

ARTICLE HISTORY

Received: 2014-05-28
Revised: 2014-06-17
Accepted: 2014-06-18

Key Words: Aquaculture, Gill filament, Histopathology, Myxozoan, plasmodium.

ABSTRACT

A myxozoan parasite, *Thelohanellus bifurcata* Basu and Haldar, 1999 infecting gills of cultured major carp, *Labeo rohita* (Hamilton, 1822), rohu was collected from 4 fish farms in Patiala district (Punjab), India. The infection rate was 20% (3/15) and the age of the fishes examined was between 3–10 months. A total of 20–30% fish mortality was recorded which included young fish between the age of 3–4 months. Plasmodia were large, visible with naked eye, oval and creamish white in color enclosing 1000–1200 spores. Spores histozoic, large, elongate pyriform in shape, tapering anteriorly with a notch-like constriction at 3/4th of the spore body and were characterized in having anteriorly bifurcated polar capsule. In histopathological sections each plasmodium occupied almost 15–25% of the gill filament. The cavity of the plasmodium was filled with spores and cellular debris. The pathogenesis caused by *T. bifurcata* was evident in cultured carps as infection caused severe damage to the gills leading to total loss of its respiratory surface. According to their location on the gill filament the plasmodia were of two types i.e. intrafilamental vascular type (FV₂) occupying the tip portion and intralamellar vascular type (LV₃) occupying side of the gill filament.

All copyrights reserved to Nexus® academic publishers

ARTICLE CITATION: Kaur H, Katoch A (2014). Gill disease caused by *Thelohanellus bifurcata* basu and haldar, 1999 a pathogenic myxozoan parasite in cultured Indian carp, *Labeo rohita* (Hamilton, 1822) in Punjab, India. J Anim. Health Prod. 2 (2): 19 – 24.

INTRODUCTION

Parasites and diseases are the serious factors in determining the success of aquaculture practices. In Punjab, fishes are generally cultured in large number in a limited area. In intensive and polyculture system, the fish pathogens can easily be transmitted through water and mud. In culture ponds, the myxosporidian infections are the most common causes of mortality thereby affecting fish production drastically. The pathological symptoms caused by myxozoan parasites have been studied by many workers such as Chakravarty (1939), Mitchell (1977), Kalavati and Narasimhamurti (1985), Awal et al., (2001), Molnar (2002), Basu and Haldar (2002, 2004), Adriano et al., (2009), Chavda et al., (2010), Campos et al., (2011), Raissy and Ansari (2011) and Kaur et al., (2013). In aquaculture, all the three major carps namely, *Labeo rohita* Hamilton, *Cirrhinus mrigala* Hamilton and *Catla catla* Hamilton have been found to be infected with myxozoan parasites (Azevedo et al., 2010; Hemananda et al., 2009, 2012; Manrique et al., 2012). Gill and dermal lesions due to myxozoan infection have been reported in many states of India (Chakravarty, 1939; Gupta and Khera, 1989; Padma Dorthy and Kalavati, 1992; Kalavati and Vaidehi, 1992; Mohan and Shanker, 1995; Kalavati and Nandi, 2007; Dar, 2013; Kaur et al., 2013). Besides this, many species of myxosporean parasites were recorded from freshwater fishes of wetlands of Punjab (Kaur and Singh, 2008, 2009, 2010a, 2010b, 2011a, 2011b, 2011c, 2011d, 2011e, 2011f, 2012a, 2012b; Singh, 2011). In Punjab, the

aquaculture is an upcoming practice being taken up by many farmers as the natural stock declined and representing it as the fastest growing animal husbandry. Presently, the area under fish culture is 10856.6ha and number of farms are 8285. However, poor knowledge of the prevailing disease causing organisms and lack of proper management practices have led to the harmful effects on fish production (Dhawan, 2006). Among myxosporidians, the two genera, *Myxobolus* and *Thelohanellus* have been recorded as the most common in aquaculture (Sarkar and Raychaudhuri, 1986; Adriano et al., 2009). In the present study, *T. bifurcata* Basu and Haldar, 1999 has been recorded for the first time from a fish pond in Punjab (earlier was reported from Nanaghat, District Nadia, West Bengal). In the present study, *T. bifurcata* Basu and Haldar, 1999 has been redescribed and its histopathology on the gills have been investigated in detail.

MATERIAL AND METHODS

Collection of Fishes

Fishes from 4 fish farms– Kuku Dala, Dhindsa, Nanoki and a Government fish farm located in district Patiala, Punjab were procured in live condition and brought to the laboratory for further investigation. Fishes ranged 25–30cm in length and were 8–10 months old. The selected ponds were polyculture having *Labeo rohita* Hamilton, *Catla catla* Hamilton, *Cirrhinus mrigala* Hamilton, *Ctenopharyngodon idellus* Valenciennes and *Cyprinus carpio* Linnaeus. The temperature

of the pond water at the time of the collection was 30–32°C. The organs such as gills, gut, eyes, fins, scales and skin were examined for infection. Infected organs were fixed in Bouin's fixative for tissue location and histopathological studies.

Preparations of Slides

Fresh Spores (Temporary Preparations)

Each plasmodium was ruptured in normal saline (0.85%) with the help of a needle on a clean slide and examined under the light microscope for the presence of spores. Fresh spores were studied in Lugol's iodine solution to confirm the presence of iodophilous vacuole. Polar filament was extruded by treating the spores with 8% KOH.

Staining of Spores (Permanent Preparations)

- i. **Fixation**: To make dry preparations thin smears were air dried, fixed in methanol and stained with Giemsa. In the case of permanent (wet) preparations, smears on clean slides were fixed in Schaudinn's and Bouin's fixatives.
- ii. **Staining**: The stains such as Heidenhain's Iron-haematoxylin and modified Ziehl-Neelsen were used to study the detailed spore morphology (Figure 2a, b)

Histopathology

Infected gills were cut into small pieces and fixed in Bouin's fixative. Tissue samples were dehydrated in ascending grades of ethanol, cleared in xylene, embedded in paraffin wax, sectioned at 3–4µm thickness and stained with haematoxylin + eosin and Luna's staining method (Luna, 1968). In Luna's method, the cysts stained bright red and rest of the gill tissue stained blue in color. This technique demonstrated the location of cysts within the gills and therefore was considered useful in histological diagnosis of the myxosporean parasites.

RESULTS AND DISCUSSION

***Thelohanellus Bifurcata* Basu and Haldar, 1999 (Tables: I, II)**

Plasmodia

Large, creamish white, oval, present on the gill filament, 3–4 in number, measure 0.8–1.5x1.5–2mm in size, 1000–1200 spores per plasmodium (Figure 1).

Spore description (Table I)

(Measurements based on 7–8 spores in frontal view)
 The spores are histozoic, large, measure 33.66x8.98µm, elongate pyriform in valvular view, tapering anteriorly with bluntly pointed anterior end and a notch-like constriction at 3/4th of the spore body, and broad rounded at the

posterior end. Shell valves thick, smooth, symmetrical measuring 0.883µm in thickness with slightly curved and distinct sutural line. Parietal folds are absent. Polar capsule is pyriform in shape measure 18.1x5.78µm, with bifurcated anterior end and rounded posterior end. Polar capsule is situated anteriorly and occupies nearly half of the spore body cavity. Polar filament form 11–14 coils arranged perpendicular to the polar capsule axis and is thick, thread-like measuring 20µm in length when extruded. Suture line is straight and distinct. Sporoplasm homogenous, granular occupies whole of the extracapsular space behind the polar capsule. An iodophilous vacuole is present, measuring 4.78µm in diameter.

Table I: Measurements (µm) and ratio of *T. bifurcata* Basu and Haldar, 1999

Characters	Range	Mean Values	SD
LS	33.16–34.16	33.66	1.53
WS	8.48–9.48	8.98	0.677
LPC	18.0–18.2	18.1	1.53
WPC	5.28–6.28	5.78	0.28
Ratio: LS/WS		3.74	
NC		11–14	
Parietal Folds		Absent	

Taxonomic summary of *T. bifurcata* Basu and Haldar, 1999

- Host : *Labeo rohita* (Ham.) vern. rohu
- Locality : Cultured farm, Patiala (Punjab)
- Site of infection : gill filament (intralamellar and intrafilamental)
- Prevalence of infection : 20% (3/15)
- Pathogenicity : highly pathogenic
- Fish mortality : 20–30%

Remarks

The present observations (LS/WS: 3.74) on *T. bifurcata* Basu and Haldar, 1999 are in conformity with the original description (LS/WS: 3.78) (Table II), however, spore and polar capsule are smaller in size in the present species. *T. bifurcata* Basu and Haldar, 1999 has been recorded for the first time from Punjab and histopathology has been done for the first time. Earlier, *T. bifurcata* Basu and Haldar, 1999 was reported as non pathogenic in the gill filaments of a hybrid of *Labeo rohita* and *Catla catla* (Kalavati and Nandi, 2007). The present study indicated extensive damage to the respiratory surface of the gills due to large sized plasmodia of *T. bifurcata* Basu and Haldar, 1999 and hence proved to be highly pathogenic to the cultured fish.

Table II: Comparative description of *T. bifurcata* Basu and Haldar, 1999 with original species (measurements are in micrometer)

Species	Host	Site of infection	Locality	Spore	Polar capsule
<i>T. bifurcata</i> (present study)	<i>Labeo rohita</i>	Gill filament	Fish farm, Patiala (Punjab)	33.66x8.98	18.1x5.78
<i>T. bifurcata</i> Basu and Haldar, 1999	<i>L. rohita</i> x <i>Catla catla</i>	Gills	Nanaghat (West Bengal)	34.8x9.2	23.3x6.6

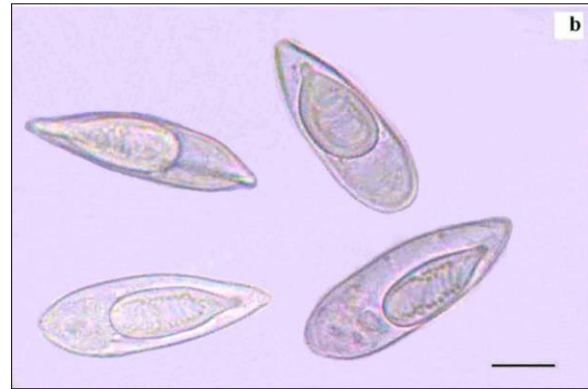
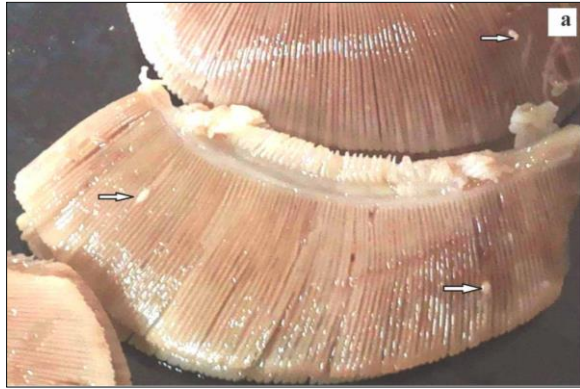


Figure 1: (a) Showing cysts(plasmodium) on the gills ↑ of *Labeo rohita* infected with *Thelohanellus bifurcata* Basu and Haldar, 1999; (b) Showing fresh spores of *T. bifurcata* Basu and Haldar, 1999

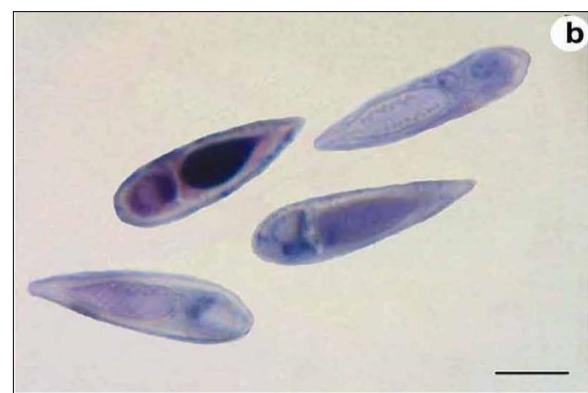
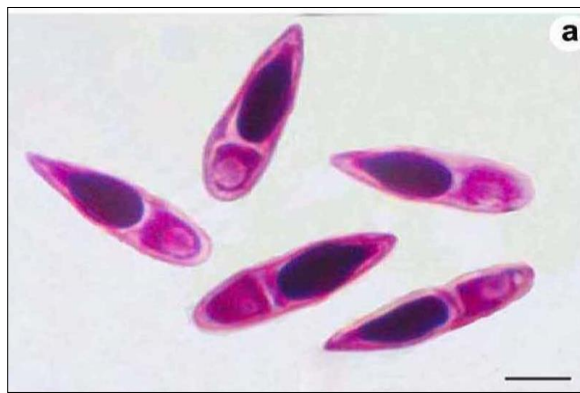
Fig. 2 (a) Spores stained with Ziehl-Neelsen; (b) Spores stained with Iron-haematoxylin

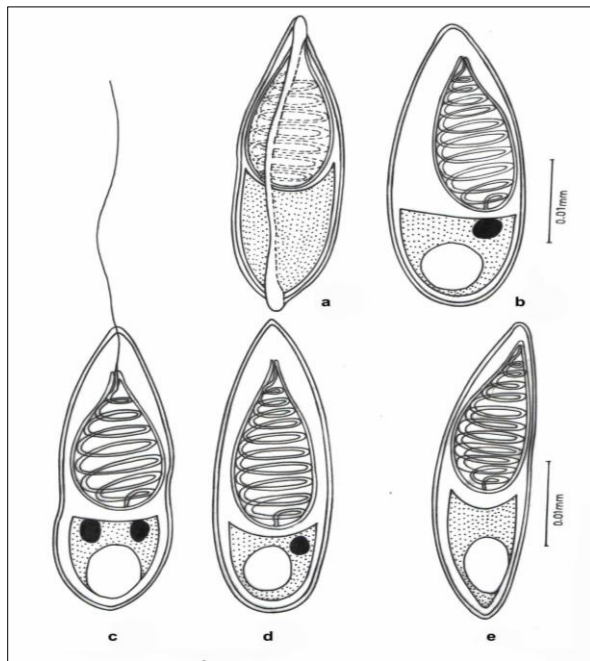


Figure 3: Line drawing (camera lucida) of *T. bifurcata* Basu and Haldar, 1999; (a) Fresh spore (sutural view); (b) Spore stained in Ziehl-Neelsen (side view); (c) Spore in frontal view (polar filament extruded); (d) spore stained in Iron-haematoxylin (valvular view); (e) spore stained in Ziehl-Neelsen (side view)

Histopathology

The present study indicated that *T. bifurcata* Basu and Haldar, 1999 as highly pathogenic parasite of gills of cultured *Labeo rohita*. The plasmodia were large, creamish white cysts visible with naked eye. 3-4 plasmodia in each gill towards the lower side of the arch were present (Figure 1a). Histopathological sections indicated the presence of cysts in two locations on the gills, one at the tip of the gill filament and other below the tip on one side of it. In the region of location of the cysts on the gill filament caused complete loss of respiratory surface. Both the plasmodia occupied up to 15–25% of the total surface area of the gill filament. Plasmodia ranged 0.8–1.5mm x 1.5–2mm in size each enclosing 1000–1200 large sized spores.

According to the location on the gill filament plasmodia were of two types and were classified as per Molnar (2002). The first type of plasmodium occupying the tip of the gill filament was intrafilamental vascular type (FV₂). This was formed by the fusion of several plasmodia into a large, oval cyst, measuring 2.00x1.5mm in size located at the tip of the filament (Figure 4). The intrafilamental vascular (FV₂) type of plasmodia of *T. bifurcata* occupied 15–20% of each gill filament. The size of the plasmodium exceeded the width of the gill filament. Several gill lamellae were fused and compressed resulting in reduction of the respiratory surface. The wall of the FV₂ plasmodia was

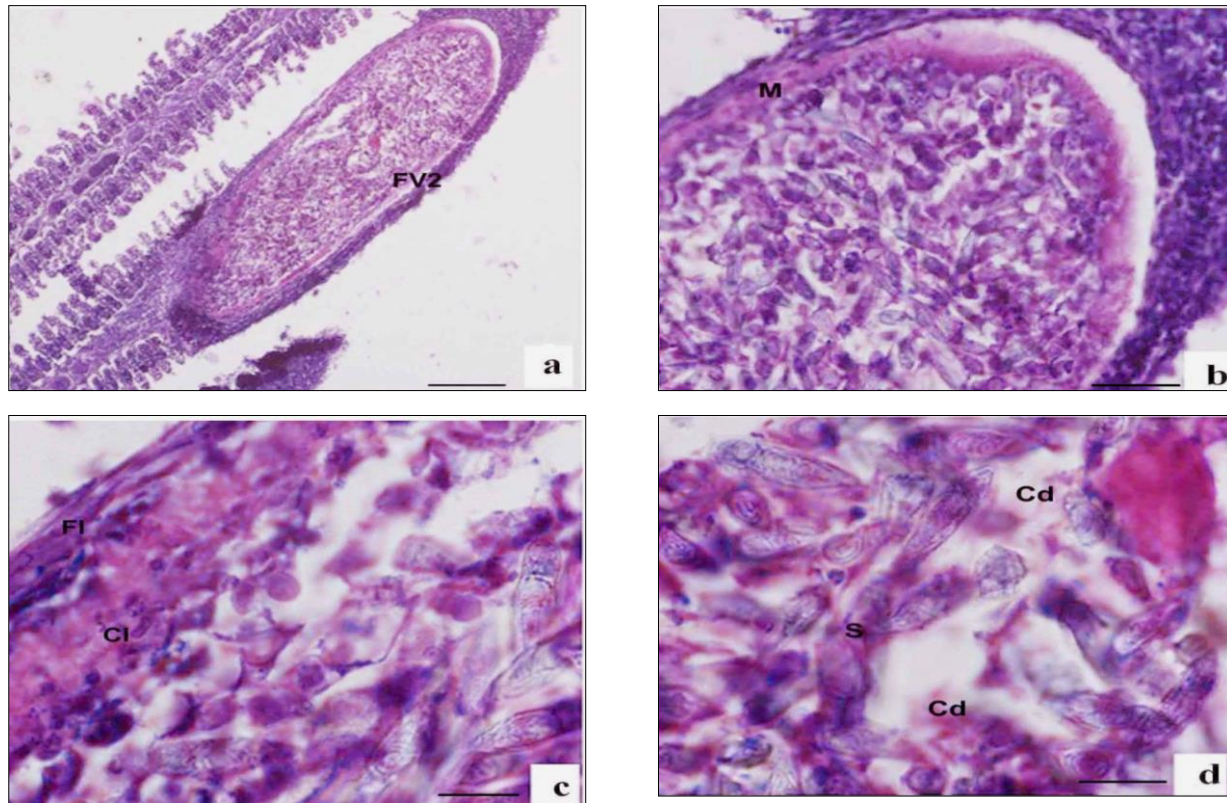


Figure 4: (a) Sagittal section of gill filament of *Labeo rohita* showing intrafilamentary vascular type (FV₂) of plasmodium of *T. bifurcata* occupying the tip of the gill filament (100x); (b) Section of gill filament of *L. rohita* showing FV₂ type plasmodium having thick double-layered bounding membrane (M) (400x); (c) Magnified view of section of FV₂ type of plasmodium showing outer fibrous layer (Fl) and inner cytoplasmic layer (Cl). (1000x); (d) Spores (S) enclosed in plasmodium along with cellular debris (Cd) (1000x).

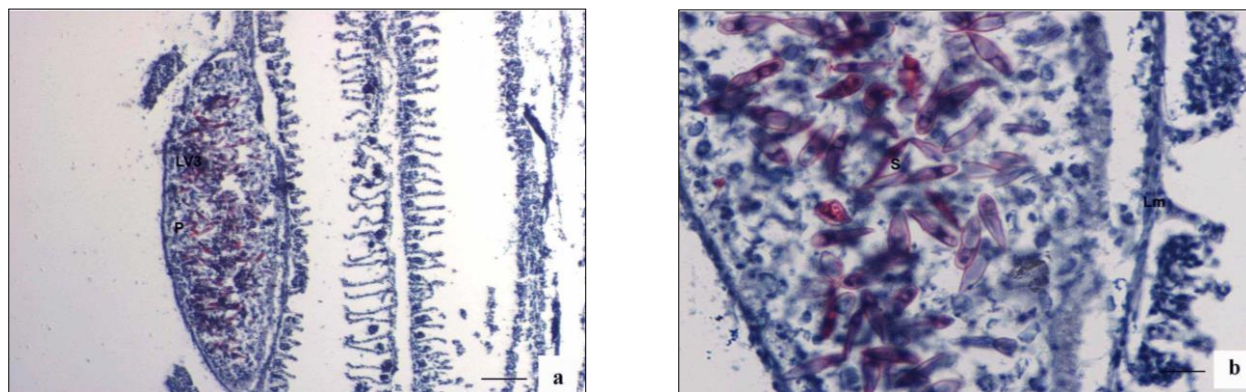


Figure 5 (a) Sagittal section of gill filament of *Labeo rohita* showing intralamellar vascular type (LV₃) of plasmodium (P) of the *T. bifurcata* protruding on one side of the gill filament (100x); (b) Magnified view of the LV₃ type of plasmodium filled with spores (S) causing total loss of respiratory surface and disruption of adjacent lamellae (Lm) (400x).

thick, made up of two layers, inner cytoplasmic measuring 0.0167mm and outer fibrous measuring 0.033mm in thickness. The lumen of the plasmodium was filled with spores and cellular debris.

The second type of plasmodia were large, oval shaped measuring 1.6x0.8mm in size and were intralamellar vascular type (LV₃), localized in vascular tissue of the gill filament. (Figure 5). This type of plasmodium occupied side of the gill filament (below the tip) and caused destruction of several gill lamellae and majority of them were no longer discernible. In contrast to FV₂ type of plasmodium, the wall

of the LV₃ was single layered made up of a thin cytoplasmic layer measuring 6µm in thickness. The cytoplasm of plasmodia was filled with debris due to destruction of vascular and cartilaginous tissue of the gill filament. Damage to the gills resulted in reduction of respiratory surface leading to severe stress due to lack of oxygen supply.

During the present study, visible plasmodia were observed on the gill filament formed by *T. bifurcata* Basu and Haldar, occupying approximately 15–25% of the total filament, supply of blood is interrupted due to the formation of LV₃ type of plasmodia within the gill filament. Adriano et

al., (2009) made similar observations that the presence of plasmodia affect the gill functions and drastically reduces the respiratory surface. Sanaullah et al., 1980 and Dykova and Lom, 1988 also reported myxoboliasis caused by myxozoans in the gills of *Catla catla* and gible carp. According to them, infected carps exhibited hemorrhagic condition with necrotic changes in the epithelia and in the connective tissues of gills. Earlier, similar observation have also been made by MacCraren et al., (1975) in gill infections of American catfish with *Henneguya exilis*, Kalavati and Narasimhamuri (1985) in *Channa punctata*, with *Henneguya waltirensis* and Rukyani (1990) in carp with *Myxobolus koi*. According to Schulman (1957) and Kalavati and Narashimhamurti (1985) rupturing of cysts can also lead to hemorrhages, sometimes resulting in considerable loss of blood as also seen in the present study. Histopathological study of the gills showed number of cysts and parasites in the gills with a slight hyperplasia of the cells and epithelium. Severe infection caused hyperplasia of the basal epithelial and goblet cells leading to increase in mucus production. The intrafilamental as well as intralamellar location of cysts was recorded to be associated with hyperplasia and inflammation. These cellular changes led to the fusion of adjoining secondary lamellae. Respiratory distress syndrome and suffocation of fishes due to myxozoan infection have also been observed by various workers such as Dykova and Lom (1978); Current and Janovy (1978); Shariff (1982); Bowser and Conroy (1985); Kalavati and Narasimhamurti (1985) and Martins et al., (1997). Some authors have also described severe lesions caused by various species of *Myxobolus* in carp leading to gill necrosis and gut degeneration (Molnar and Kovacs-Gayer, 1985; Dykova and Lom, 1988). Barassa et al., (2003), Eiras et al., (2008, 2009) and Adriano et al., (2009) reported the histological analyses of gills infected with myxozoan parasites revealed presence of numerous large cysts in the gill filaments, but no pronounced inflammatory response was found in the infection site as also evident from the present study. The structural alterations in the gills are similar to structural changes reported for other myxosporean species (Feist and Longshaw, 2006). The wall of the plasmodia is double layered outer is fibrous and inner is cytoplasmic, similar observations were made by Casal et al., (2002, 2006) but differed from single layered plasmodia studied by Current et al., 1979. Gill infections by myxoporeans in farmed fish can cause significant tissue damage and occasionally death (Martins et al., 1999; Adriano et al., 2005a, 2005b; Feist and Longshaw, 2006).

ACKNOWLEDGEMENTS

The authors acknowledge for providing financial support by University Grants Commission (UGC) Govt. of India in the form of Major Research Project (MRP).

CONFLICT OF INTEREST

No conflict of interest.

REFERENCES

- Adriano EA, Arana S, Alves AL, Silva MR, Ceccarelli PS, Henrique-Silva F, Maia AA (2005a) Histology, ultrastructure and prevalence of *Henneguya piaractus* (Myxosporea) infecting *Prochilodus lineatus* (Pisces: Prochilodontidae) cultivated in Brazil. Dis. Aquatic Org. 64: 229–235.
- Adriano EA, Arana S, Alves AL, Silva MR, Ceccarelli PS, Henrique-Silva F, Maia AA. (2005b). Histology, ultrastructure and prevalence of

- Henneguya caudalongula* sp. n. (Myxosporea) infecting *Prochilodus lineatus* (Pisces: Prochilodontidae) cultivated in State of Sao Paulo, Brazil. Mem. Inst. Oswaldo Cruz. 100:177–181.
- Adriano EA, Arana S, Alves AL, Silva MR, Ceccarelli PS, Henrique-Silva F, Maia AA (2009). *Myxobolus cordeiroi* n. sp., a parasite of *Zungaro jahu* (Siluriformes: Pimelodiade) from Brazilian Pantanal: morphology, phylogeny and histopathology. Vet. Parasitol. 162: 221–229.
- Awal MA, Begum AA, Chandra KJ, Ahmed GU, Kurohmaru M (2001). Myxosporidian infection of gills and skin among carp from nursery ponds in Bangladesh: histopathology. Vet. Arhiv. 71(5): 265–276.
- Azevedo C, Casal G, Mendonça I, Carvalho E, Matos P, Matos E (2010). Light and electron microscopy of *Myxobolus sciades* n. sp. (Myxozoa), a parasite of the gills of the Brazilian fish *Sciades herzbergii* (Block, 1794) (Teleostei: Ariidae). Mem. Inst. Oswaldo Cruz. 105(2): 203–207.
- Barassa B, Adriano EA, Cordiero NS (2003). *Henneguya curvata* n. sp. (Myxosporea: Myxobolidae) parasitizing the gills of *Serrasalmus spilopleura* (Characidae : Serrasalminae), a south American fresh water fish. Folia Parasitol. 50: 151–153.
- Basu S, Haldar DP (1999). *Thelohanelus bifurcata* n. sp. a new species of the genus *Thelohanelus* from hybrid carps and checklist of the species of the genus described from Indian fishes. Proc. Zool. Soc. 52(1), 115–124.
- Basu S, Haldar DP (2002). *Myxobolus ophthalmusculata*, a new species of histozoic myxozoan (Myxozoa: Bivalvulida) from *Cirrhinus mrigala* (Hamilton). Proc. Zool. Soc. 55(2): 43–48.
- Basu S, Haldar DP (2004). Description of three new species (Myxozoa: Myxosporea: Bivalvulida) of the genera *Myxobilatus* Davis, 1944 and *Myxobolus* Butschli, 1882. Acta Protozool. 43 (4): 337–343.
- Bowser PR, Conroy JD (1985). Histopathology of gill lesions in channel catfish associated with *Henneguya*. J. Wildlife Dis. 21(2):177–179.
- Casal G, Matos E, Azevedo C (2002). Ultrastructural data on the spore of *Myxobolus maculatus* n. sp. (Phylum Myxozoa) parasite from American fish *Metynnis argenteus* (Teleostei). Dis. Aquatic Org. 51: 107–112.
- Casal G, Matos E, Azevedo C (2006). A new Myxozoan parasites from the Amazonian fish *Metynnis argenteus* (Teleostei, Characidae): Light and electron microscope observations. J. Parasit. 92: 817–821.
- Campos CM, Moraes JRE, Moraes FR (2011). Histopathology of gills of *Piaractus mesopotamicus* (Holmberg, 1887) and *Prochilodus lineatus* (Valenciennes, 1836) infested by monogenean and myxosporea, caught in Aquidauana river, State of Mato Grosso do Sul, Brazil. Rev. Bras. Parasitol.Vet. 20: 67–70.
- Chakravarty MM (1939). Studies on myxosporidia from fishes of Bengal, with a note on myxosporidian infection in aquaria fishes. Arch. Protistenkunde. 92: 169–178.
- Chavda D, Bhatt S, Sreepada RA, Sheth A (2010). Pathogenicity of *Myxobolus* infection and its effect on protein expression in *Catla catla* in central Gujarat region. J. Cell Tissue Res. 10(1): 2157–2164.
- Current WJ, Janovy J (1978). Comparative study of ultrastructure of interlamellar and intralamellar types of *Henneguya exilis* Kudo from channel catfish. J. Protozool. 25: 56–65.
- Current WJ, Janovy J (1979). *Myxosoma funduli* Kudo (Myxosporidia) in *Fundulus kansae*: ultrastructure of plasmodium wall and of sporogenesis. J. Protozool. 26: 574–583.
- Dar SA (2013). Identification and distribution of myxozoan parasites infecting aquaculture fishes of district Patiala, Punjab. Dissertation. Punjabi University, Patiala (India)
- Dhawan A (2006). Diversification from major carp farming—promising option in Punjab. Fish. Chimes. 25(10): 136–140.
- Dykova I, Lom J (1978). Histopathological changes in fish gills infected with myxosporidian parasites of genus *Henneguya*. J. Fish Biol.12: 197–202.
- Dykova I, Lom J (1988) Review of pathogenic myxosporeans in intensive culture of carp (*Cyprinus carpio*) in Europe. Folia Parasitol. 36: 289–307.
- Eiras JC, Takemoto RM, Pavanelli GC (2008). *Henneguya caudicula* n. sp. (Myxozoa, Myxobolidae) a parasite of *Leporinus lacustris* (Osteichthyes, Anostomidae) from high Parana river, Brazil, with revision of *Henneguya* spp infecting South American fish. Acta Protozool. 47: 149–154.
- Eiras JC, Takemoto RM, Pavanelli GC (2009). *Henneguya corruscans* n. sp. (Myxozoa, Myxobolidae) a parasite of *Pseudoplatystoma corruscans* (Osteichthyes, Anostomidae) from Parana river, Brazil, a morphological and morphometric study. Vet. Parasitol. 159:154–158.
- Feist SW, Longshaw M (2006). In: Fish diseases and disorders. Protozoan and Metazoan Infections (ed. by P.T.K. Woo), pp. 230–296. CAB International, Oxfordshire.
- Gupta S, Khera S (1989). Observations on *Myxobolus punjabensis* sp. nov. (Myxozoa:Myxobolidae),parasitic on gills and fins of *Labeo dyocheilus*. Riv. Parasitol.50:131–138.
- Hemananda T, Mohilal N, Bandyopadhyay PK, Mitra AK (2009). Two new myxosporidia (Myxozoa: Myxosporea) of the genus *Myxobolus* Butschli, 1882 from cornea of *Clarias batrachus* (Linnaeus, 1758) caught from fish

- farm in India. *N-W J. Zool* 5(1), 165–169.
- Hemananda T, Mohilal N, Bandyopadhyay PK, Mitra AK (2012) *Myxobolus leafa* sp. nov. (Myxozoa: Bivalbulida) from the gill filament of *Labeo bata* (Hamilton) from Manipur, India. *Türkiye Parazitol. Derg.* 37: 40–43.
- Kalavati C, Nandi NC (2007). Handbook of Myxosporidean parasites of Indian fishes. ZSI, India, Kolkata.
- Kalavati C, Narasimhamurti CC (1985). Histopathological changes in the gills of *Channa punctatus* BL, infected with *Henneguya waltirensis*. *Arch. Protistenkunde.* 129:199–202.
- Kalavati C, Vaidehi J (1992). A new myxosporidian, *Thelohanelus chilkenis* n. sp. from gills of the common carp, *Labeo rohita* in Chilka lake, India. *Riv. Parasit.* 33(57):79–82.
- Kaur H, Katoch A, Dar SA, Singh R (2013). *Myxobolus nanokiensis* sp. nov. (Myxozoa: Bivalbulidae), a new pathogenic myxosporean parasite causing haemorrhagic gill disease in cultured Indian major carp fish, *Labeo rohita* (Hamilton 1822) in Punjab, India. *J. Parasitic Dis.* doi: 10.1007/s12639-013-0351-0.
- Kaur H, Singh R (2008). Observations on one new species of genus *Myxobolus* – *M. naini* and redescription of *M. magauddi* recorded from freshwater fishes of Kanjali Wetland of Punjab, India. *Proceedings of 20th National Congress of Parasitology NEHU Shillong, India.* pp. 75–79.
- Kaur H, Singh R (2009). A new myxosporean species, *Myxobolus cirasi* sp. nov., a known species *M. venkateshi* Seenappa and Manohar (1981) from the Indian major carp fish *Cirrhina mrigala* (Ham). *Protistology* 6: 126–130.
- Kaur H, Singh R (2010a). A new myxosporean species *Myxobolus sclerii* sp. nov. and one known species *M. stomum* Ali et al. (2003) from two Indian major carp fishes. *J. Parasitic Dis.* 34: 33–39.
- Kaur H, Singh R (2010b). One new myxosporidian species, *Myxobolus slendrii* sp. nov., one known species, *M. punjabensis* Gupta, Khera (1989) infecting freshwater fishes in wetlands of Punjab, India. *Parasitol. Res.* 106, 1043–1047.
- Kaur H, Singh R (2011a) Two new species of *Myxobolus* (Myxozoa: Myxosporidia: Bivalbulida) from freshwater fishes of Punjab wetlands (India). *J. Parasitic Dis.* 35: 33–41.
- Kaur H, Singh R (2011b) Two new species of *Myxobolus* (Myxozoa: Myxosporidia: Bivalbulida) infecting an Indian major carp in Ropar and Kanjali wetlands (Punjab). *J. Parasitic Dis.* 35(1) : 23–32.
- Kaur H, Singh R (2011c) Two new species of *Myxobolus* (Myxozoa: Myxosporidia: Bivalbulida) infecting an Indian major carp and a cat fish in wetlands of Punjab, India. *J. Parasitic Dis.* 35:169–176.
- Kaur H, Singh R (2011d) Two new species of *Myxobolus* (Myxozoa: Myxosporidia: Bivalbulida) infecting Indian freshwater fishes in Punjab wetlands (India). *Parasitol. Res.* 108, 1075–1082.
- Kaur H, Singh R (2011e). *Myxobolus harikensis* sp. nov. (Myxozoa: Myxobolidae) infecting fins of *Cirrhina mrigala* (Ham.), an Indian major carp in Harike wetland, Punjab (India). *Parasitol. Res.* 109:1699–1705.
- Kaur H, Singh R (2011f). Two new and one already known species of *Myxobolus* (Myxozoa: Myxosporidia: Bivalbulida) infecting gill lamellae of Indian major carp fishes in Ropar and Harike wetlands (Punjab). *Proceedings of 22nd National Congress of Parasitology, University of Kalyani West Bengal, India.* pp. 81–90.
- Kaur H, Singh R (2012a). A synopsis of the species of *Myxobolus* Bütschli, 1882 (Myxozoa: Bivalbulida) parasitizing Indian fishes and a revised dichotomous key to myxosporean genera. *Syst. Parasitol.* 81: 17–37.
- Kaur H, Singh R (2012b). One new myxosporean species, *Triangula cirrhini* sp. n., and one known species, *T. ludhiana* (syn. *M. ludhiana* Gupta and Khera, 1991) comb. n. (Myxozoa: Myxosporidia), infecting Indian major carp in Harike wetland of Punjab. *Anim. Biol.* 62: 129–139.
- Luna LG (1968). Manual of histologic staining method of the Armed Forces Institute of Pathology, pp. 111.
- MacCraren JP, Landolt MM, Hoffman GL (1975). Variation in response of Channel catfish to *Henneguya* sp. infections (Protozoa: Myxosporidia). *J. Wildlife Dis.* 11:2–7.
- Manrique WG, Claudiano GS, Figueiredo MAP, Petrillo TG, Moraes JRE, Moraes FR (2012). Myxosporidiosis in intensively-reared *Piaractus mesopotamicus*: Histopathological diagnosis by means of Ziehl–Neelsen staining. *Pesq. Vet. Bras.* 32(11): 1133–1137.
- Martins ML, Souza VN, Moraes FR, Moraes JRF, Costa AJ, Rocha U F (1997). Pathology and behavioral effects associated with *Henneguya* sp. (Myxozoa: Myxobolidae) infections of captive *Piaractus mesopotamicus* in Brazil. *J. World Aq. Soc.* 28: 297–300.
- Martins ML, Souza VN, Moraes FR, Moraes JRF, Costa AJ, Rocha UF (1999). Gill infection of *Leporinus macrocephalus* Garavello & Britski, 1988 (Osteichthyes: Anostomidae) by *Henneguya leporinicola* n. sp. (Myxozoa: Myxobolidae). Description, histopathology and treatment. *Rev. Bras. de Parasit. Vet.* 59(3): 527–534.
- Mitchell LG (1977). Myxosporidia. In: Kreier JP (ed.) *Parasitic Protozoa.* Academic Press Inc New York. 4:115–154.
- Mohan CV, Shankar KM (1995). Pathogenic myxosporean infection in early fry of Indian major carp, *Catla catla*. *Curr. Sci.* 68(5): 548–551.
- Molnar K (2002). Site preference of fish myxosporidia in the gill. *Dis. Aq. Org.* 48: 197–207.
- Molnar K, Kovács–Gayer E (1985). The pathogenicity and development within the host fish of *Myxobolus cyprini* Doflein. *Parasitology*, 90: 549–555.
- Padma Dorothy K, Kalavati (1992). Two myxosporean parasites of the mullet, *Liza macrolepis* (Smith). *Acta Protozool.* 32: 123–125.
- Raissy M, Ansari M (2011). Histopathological changes in the gills of naturally infected *Capoeta aculeate* (Cuvier and Valenciennes, 1844) with parasites. *African J. Biotech.* 10(68): 15422–15425.
- Rukyani A (1990). Histopathological changes in gills of common carp (*Cyprinus carpio* L.) infected with the myxosporean parasite *Myxobolus koi* Kudo, 1920. *Asian Fish. Sci. J.* 3:337–341.
- Sanaullah M, Ahmed ATA (1980). Gill myxoboliasis of major cars in Bangladesh. *J. Fish Dis.* 3: 349–354.
- Schulman SS (1957). The pathogenicity of the myxosporidian *Myxobolus exiguus* in correlation to its epizootics. *Parasites and diseases of fish.* *Bull. Inst. Freshwater Fish.* 42: 326–328.
- Shariff N (1982). *Henneguya shaharini* sp. nov. (Protozoa: Myxozoa), a parasite of marble goby, *Oxieleotrix marmoratus* (Bleeker). *J. Fish Dis.* 5: 37–45.
- Sarkar NK, Raychaudhuri S (1986). *Thelohanelus bengalensis* sp. n. and *Myxidium mystium* sp. n. (Myxozoa): Two new myxosporidia from Indian freshwater teleost. *Acta Protozool.* 25 (3): 359–362.
- Singh R (2011). A study on the myxozoan parasites of the fishes of Punjab wetlands. Ph.D Thesis. Punjabi University, Patiala.