

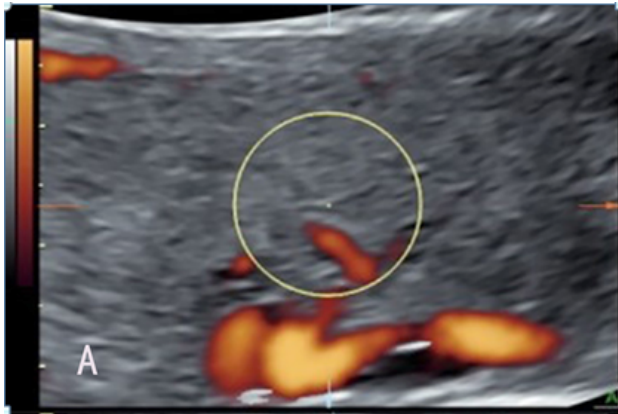

Supplementary Material

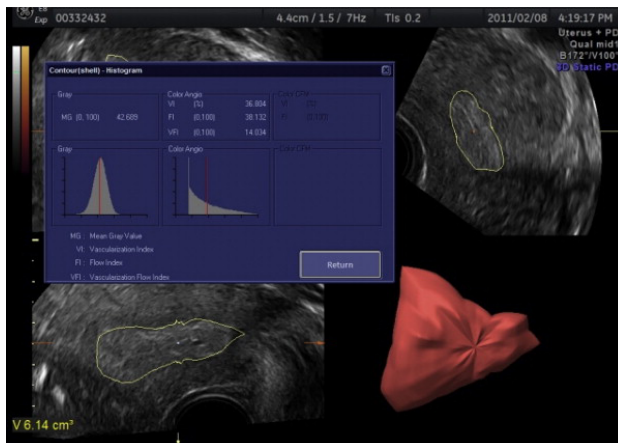
Assessment of Three Dimensional Color Power Doppler Technique for Detecting Fetal Renal Vascular Perfusion in Pregnant Women with Gestational Hypertension

Hong Liu and Rui Xu*

Obstetrics and Gynecology Department, The Third People's Hospital of Lixia District of Jinan City, Jinan, 2500000, China



Supplementary Fig. 1. 3D-CPA imaging of fetal kidney.



Supplementary Fig. 2. 3D-CPA volume image of fetal kidney.

* Corresponding author: xurui0739@126.com
0030-9923/2022/0003-1431 \$ 9.00/0
Copyright 2022 Zoological Society of Pakistan